Changes in colposcopy terminology: from disease recognition to pattern recognition

MARIO SIDERI

ISTITUTO EUROPEO DI ONCOLOGIA
Milano

ROLE OF COLPOSCOPY

Colposcopy has a central role in the management of patients with abnormal screening test

THE ROLE OFCOLPOSCOPY

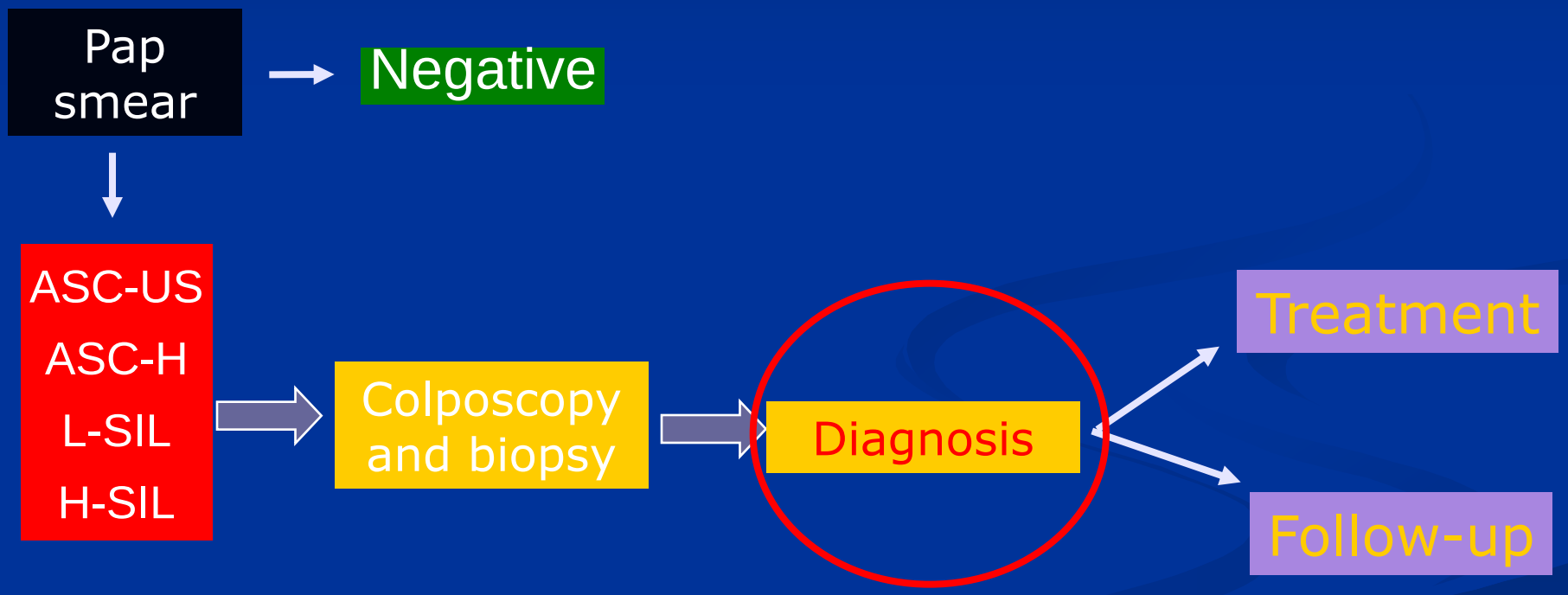

WHAT IS COLPOSCOPY?

COLPOSCOPY HAS TWO DIFFERENT AIMS

Biopsy result

- disease recognition
- patient management

flow charts

DISEASE RECOGNITION

It is generally agreed to consider the biopsy result as the final outcome of the colposcopic examination

ASCCP 06

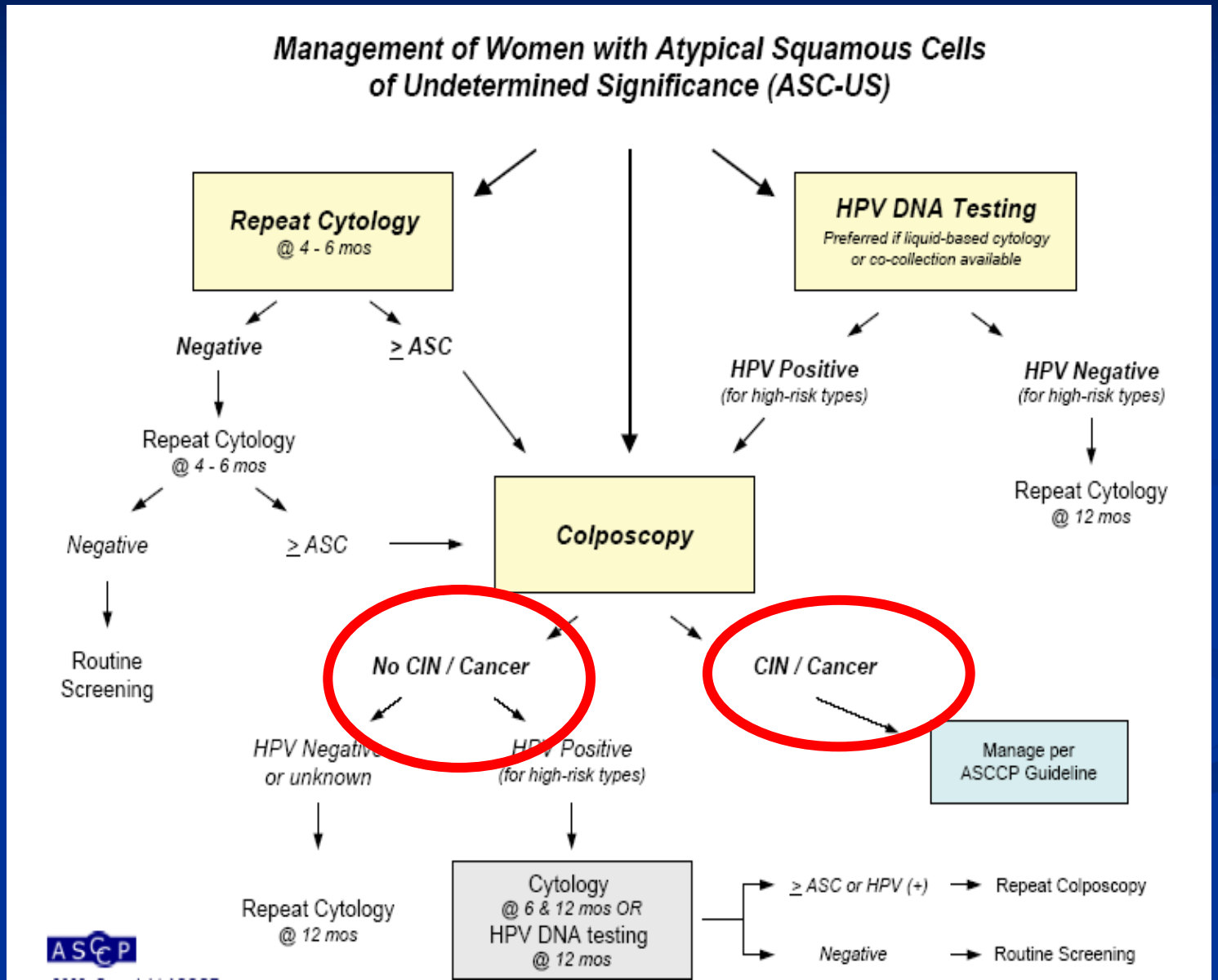
Management of Women with Atypical Squamous Cells of Undetermined Significance (ASC-US)
Repeat Cytology
@ 4 - 6 mos
HPV DNA Testing
Preferred if liquid-based cytology or co-collection available
Negative
≥ ASC
HPV Positive
(for high-risk types)
HPV Negative
(for high-risk types)
Repeat Cytology
@ 4 - 6 mos
Repeat Cytology
@ 12 mos
Negative
≥ ASC
Colposcopy
Routine Screening
No CIN / Cancer
CIN / Cancer
HPV Negative or unknown
HPV Positive
(for high-risk types)
Manage per ASCCP Guideline
Repeat Cytology
@ 12 mos
Cytology
@ 6 & 12 mos OR
HPV DNA testing
@ 12 mos
≥ ASC or HPV (+)
Repeat Colposcopy
Negative
Routine Screening
ASCCP

Considering colposcopy as the histology results of a colposcopic directed biopsy is very reductive of the value of the colposcopic exam

PERFORMANCE of COLPOSCOPY

- Which is the performance of colposcopy?

Colposcopically directed biopsy, random cervical biopsy, and endocervical curettage in the diagnosis of cervical intraepithelial neoplasia II or worse

Robert G. Pretorius, MD,[a,*] Wen-Hua Zhang, MD,[b] Jerome L. Belinson, MD,[c]
Man-Ni Huang, MD,[b] Ling-Ying Wu, MD,[b] Xun Zhang, MD,[b]
You-Lin Qiao, MD, PhD[b,**]

- 364 CIN2+ with fully visible SCJ
- 57.1% colposcopy directed bx
- 37.4% random biopsy
- 5.5% ECC (1/20 invasive K)

American Journal of Obstetrics and Gynecology (2004) **191**, 430–4

The accuracy of colposcopic biopsy: analyses from the placebo arm of the Gardasil clinical trials

Mark H. Stoler[1], Michelle D. Vichnin[2], Alex Ferenczy[3], Daron G. Ferris[4,5], Gonzalo Perez[6], Jorma Paavonen[7], Elmar A. Joura[8], Henning Djursing[9], Kristján Sigurdsson[10,11], Lucy Jefferson[12], Frances Alvarez[2], Heather L. Sings[2], Shuang Lu[2], Margaret K. James[2], Alfred Saah[2] and Richard M. Haupt[2] for the FUTURE I, II and III Investigators

Int. J. Cancer: **128**, 1354–1362 (2011)

Table 2. Correlation between the most severe diagnosis for the definitive excisional procedure specimen and the most severe diagnosis for the biopsy taken on the same day immediately before the definitive excisional procedure (Analysis II)

		Definitive Excisional Procedure Diagnosis				
		Negative	CIN1	CIN2	CIN3/AIS	Total
Cervical Biopsy Diagnosis	Negative	195	82	29	54	360
	CIN1	12	65	28	17	122
	CIN2	1	2	21	25	49
	CIN3/AIS	7	4	3	49	63
	Total	215	153	81	145	594

Overall perfect agreement: 56% (330/594)

Biopsy underestimates disease: 40% (235/594)

Biopsy overestimates or removes disease: 5% (29/594)

Overall underestimation of CIN2-3/AIS: 57% (128/226)

Overall underestimation of CIN3/AIS: 66% (96/145)

ATHENA TRIAL
A standardized approach of colposcopy with biopsy/ECC*

Colpo	**Satisfactory** *(Visualization of cervix & SCJ)*		**Unsatisfactory** *(Partial visualization of SCJ)*		**Unsatisfactory** *(SCJ not visualized)*	
	Lesion(s) visible	No lesion visible	Lesion(s) visible	No lesion visible	Lesion(s) visible	No lesion visible
Biopsy	**All lesions**	**Single biopsy at SCJ**	**All lesions**	**Single biopsy at SCJ**	**All lesions**	**No**
ECC	✗	✗	✗	✓	✓	✓

* Colposcopy was conducted according to the principles recommended by the American Society for Colposcopy and Cervical Pathology

Random biopsies in women in the overall ATHENA population

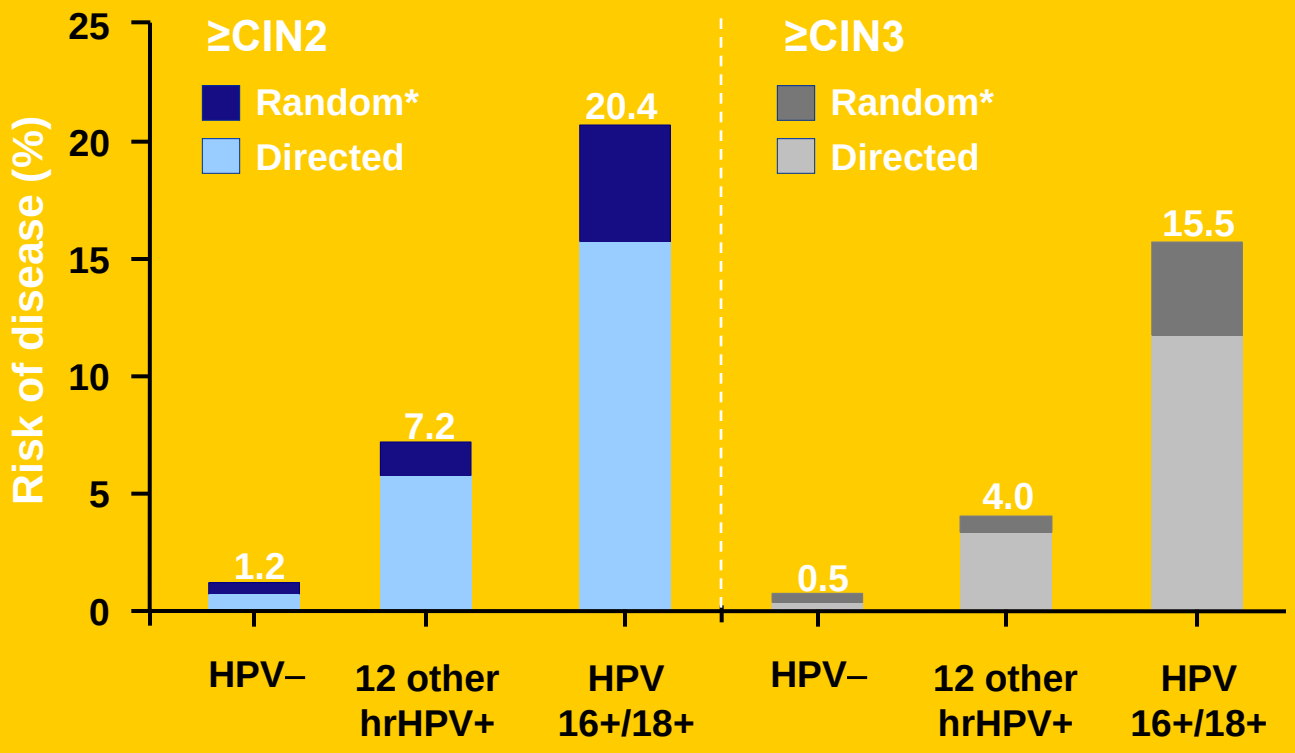

* Random biopsies performed in women in which no lesions were visualized

Huh W, *et al.* ACOG Annual Clinical Meeting. Washington DC, US, 2011. Oral presentation.

Is the Colposcopically Directed Punch Biopsy a Reliable Diagnostic Test in Women With Minor Cytological Lesions?

Esther L. Moss, PhD,[1] Paula Hadden[1] Gill Douce, FRCPath,[2] Peter W. Jones, PhD,[3] Marc Arbyn, MD, DrTMH,[4] and Charles W.E. Redman, MD[1]

Table 2. Sensitivity, Specificity, and Positive and Negative Predictive Values of a Single Colposcopically Directed Punch Biopsy Compared With the Gold Standard Histological Diagnosis (LEEP)

Test cutoff (punch biopsy)	Outcome (LEEP)	Sensitivity, %	Specificity, %	Positive predictive value, %	Negative predictive value, %
CIN 1+	CIN 2+	66.7	72.3	51.9	82.9
CIN 1+	CIN 3+	75.0	65.0	22.2	95.1
CIN 2+	CIN 2+	28.6	100.0	100.0	75.8
CIN 2+	CIN 3+	50.0	96.7	66.7	93.5
CIN 3+	CIN 3+	37.5	100.0	100.0	92.3

colposcopy. A CIN 2+ punch biopsy justifies LEEP, but a negative punch biopsy result is insufficient to exclude CIN 2 or 3 in this group.

Number of Cervical Biopsies and Sensitivity of Colposcopy

*Julia C. Gage, MPH, Vivien W. Hanson, MD, Kim Abbey, BSN, FNP, Susan Dippery, RN, WHCNP, Susi Gardner, BSN, MSN, ARNP, Janet Kubota, BSN, WHCNP, Mark Schiffman, MD, MPH, Diane Solomon, MD, and Jose Jeronimo, MD, for The ASCUS LSIL Triage Study (ALTS) Group**

Table 3. Enrollment Colposcopically Directed Biopsy Result Among Patients With a 2-Year Cumulative Final Disease Outcome of CIN 3+, by Number of Biopsies Taken at Enrollment Exam*

	Number of Biopsies Taken						
	One		Two		Three or More		
Enrollment Colposcopically Directed Biopsy Result*		Cumulative %		Cumulative %		Cumulative %	$p^{\dagger}$
CIN 3+	108 (51.9)	51.9	87 (65.9)	65.9	24 (57.1)	57.1	.02
CIN 2	34 (16.4)	68.3	21 (15.9)	81.8	11 (26.2)	83.3	<.01
Atypia-CIN 1	27 (13.0)	81.3	13 (9.9)	91.7	4 (9.5)	92.9	<.01
Normal/benign abnormality	39 (18.8)	100.0	11 (8.3)	100.0	3 (7.1)	100.0	NA

CIN, cervical intraepithelial neoplasia; NA, not applicable.
Data are n (%) or %.
*As read by Pathology Quality Control Group.
† By χ^2 test comparing cumulative percent of one with two or more biopsies.

OBSTETRICS & GYNECOLOGY
VOL. 108, NO. 2, AUGUST 2006

This is not the result of colposcopy.

This is the pathology result of one or more biopsies

The state of the art

- sensitivity of colposcopy lower than previously expected
- low reproducibility of colposcopic impression
- number of biopsies (two or more), “random” biopsy, ECC, can improve sensitivity
- colposcopy is going to die, when facing the burden of cancer prevention in developing countries (as the pap smear…)

Which is the current colposcopic terminology?

Current terminology is focused on the description of the colposcopic findings

Colposcopic terms are never integrated into the management algorithm

Present terminology is a wording code for colposcopists

Which is the current colposcopic terminology?

Table 1. International Federation for Cervical Pathology and Colposcopy Colposcopic Classification

I.	Normal colopscopic findings
	Original squamous epithelium
	Columnar epithelium
	Transformation zone
II.	Abnormal colposcopic findings
	Flat acetowhite epithelium
	Dense acetowhite epithelium*
	Fine mosaic
	Coarse mosaic*
	Fine punctation
	Coarse punctation*
	Iodine partial positivity
	Iodine negativity*
	Atypical vessels*
III.	Colposcopic features suggestive of invasive cancer

*Major changes.

Which is the current colposcopic terminology?

Current terminology is the description of what is seen.

The colposcopic appearances should be translated into diagnostic groupings.

The diagnostic groupings should have a clinical meaning and be reproducible

The "new" colposcopic terminology

2011 IFCPC colposcopic terminology of the cervix[1]	
General assessment	• Adequate/inadequate for the reason … (i.e.: cervix obscured by inflammation, bleeding, scar) • Squamo-columnar Junction visibility: completely visible, partially visible, not visible • Transformation zone types 1,2,3

- Adeguata/non adeguata
- Visibilità GSC, in tre classi
- Tre tipi di ZT

The “new” colposcopic terminology

Normal colposcopic findings		Original squamous epithelium: • Mature • Atrophic Columnar epithelium • Ectopy Metaplastic squamous epithelium • Nabothian cysts • Crypt (gland) openings Deciduosis in pregnancy	
Abnormal colposcopic findings	**General principles**	**Location of the lesion**: Inside or outside the T-zone, Location of the lesion by clock position **Size of the lesion**: Number of cervical quadrants the lesion covers, Size of the lesion in percentage of cervix,	
	Grade 1 (Minor)	Thin aceto-white epithelium Irregular, geographic border	Fine mosaic, Fine punctation
	Grade 2 (Major)	Dense aceto-white epithelium, Rapid appearance of acetowhitening, Cuffed crypt (gland) openings	Coarse mosaic, Coarse punctuation, Sharp border, Inner border sign, Ridge sign
	Non specific	Leukoplakia (keratosis, hyperkeratosis), Erosion Lugol’s staining (Schiller’s test): stained/non-stained	
Suspicious for invasion		Atypical vessels **Additional signs**: Fragile vessels, Irregular surface, Exophytic lesion, Necrosis, Ulceration (necrotic), tumor/gross neoplasm	

ALTERNATIVE VIEW

Is it possible to use colposcopy as a stand alone exam, and integrate the results with pap smear and molecular tests into the management algorithm?

PATTERN vs DISEASE RECOGNITION

Biopsy result

Colposcopy results

- disease recognition

Vs

- pattern recognition

PATTERN RECOGNITION

- lesion detection and grading
- TZ type

There is a new area to explore for the integration of colposcopy into the management algorithm

Changing the colposcopic classification into reproducible *diagnostic* (vs descriptive) colposcopic categories.

COLPOSCOPIC DIAGNOSTIC CATEGORIES

- clinically meaningful
- reproducible

Evaluating the Risk of Cervical Precancer with a Combination of Cytologic, Virologic, and Visual Methods

Sophia S. Wang[1] Joan L. Walker[3] Mark Schiffman[1] Diane Solomon,[2]
and for the Atypical Squamous Cell of Undetermined Significance/
Low-Grade Squamous Intraepithelial Lesion Triage Study Group

Risk of CIN2± in patients with ASC-US, or L-SIL, on the basis of the combination of three exams only:

- *pap smear (LBC)*
- *HPV-DNA test (HC2)*
- *Colposcopy (visual impression)*

PAP L-SIL, hr-HPV positive

287/1160		24.7% (22.3-27.3)
Visual assessment	No. CIN2$^+$/total	Risk, % (95% CI)
Normal	89/500	17.8 (14.5-21.4)
Atypical	62/241	25.7 (20.3-31.7)
Low grade	114/361	31.6 (26.8-36.6)
High grade/cancer	16/33	48.5 (30.8-66.5)
294/412		71.4% (66.7-75.7)
Visual assessment	No. CIN2$^+$/total	Risk, % (95% CI)
Normal	67/117	57.3 (47.8-66.4)
Atypical	37/65	56.9 (44.0-69.2)
Low grade	146/176	83.0 (76.6-88.2)
High grade/cancer	39/43	90.7 (77.9-97.4)

PAP H-SIL, hr-HPV positive

Colposcopic diagnostic categories: Clinically meaningful

The risk of CIN2+ in L-SIL or H-SIL, HPV DNA positive, stratified on the basis of colposcopy only, varies from 17% to 90%.

DIAGNOSTIC PROCESS
How to increase reproducibility

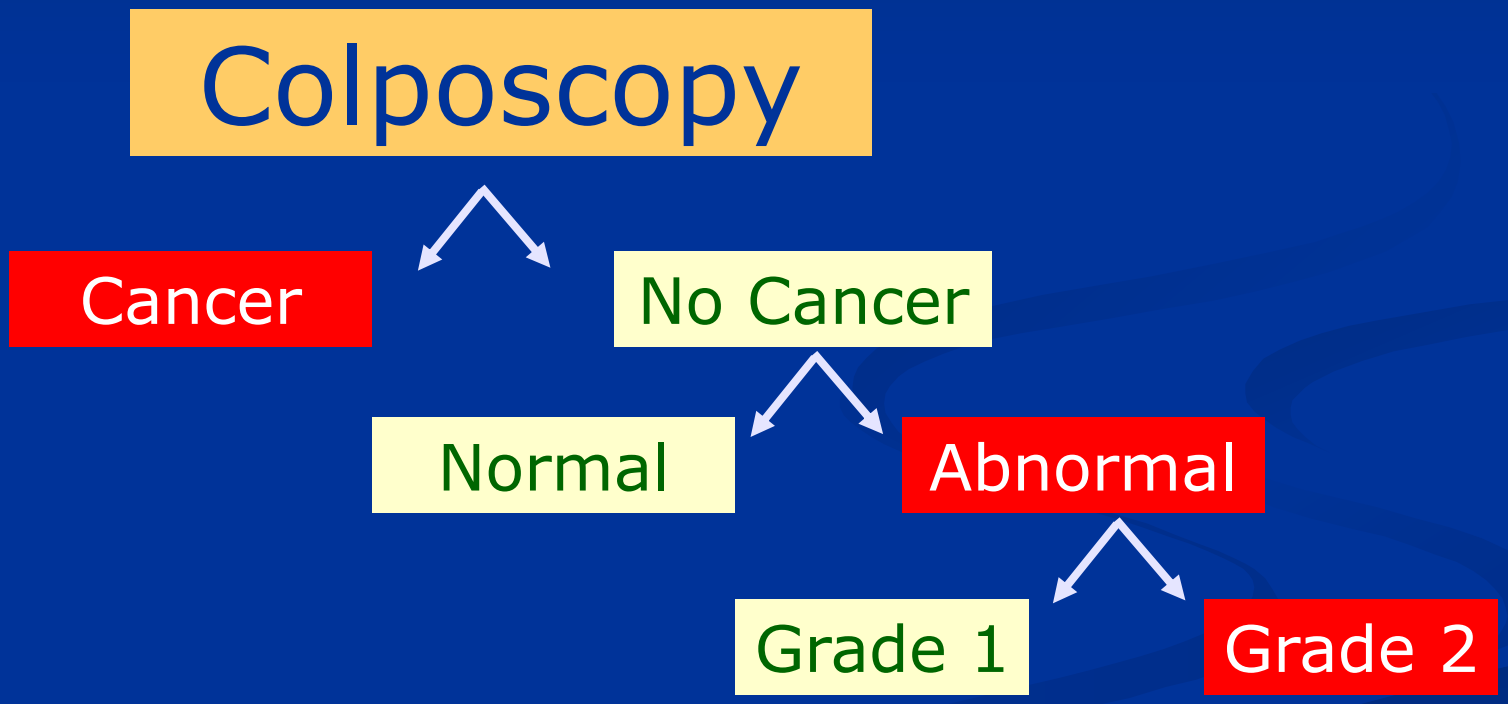

TZ CLASSIFICATION

- Type 1, small, large
- Type 2, small, large
- Type 3, no lesion, small,large

CONCLUSION

Colposcopy as a stand alone exam is an alternative to multiple biopsies in the view of replacing clinical protocols with risk stratification.

In this way the power of new molecular tests is optimized and not constrained into the bottle neck of colpo/random directed biopsies.

CONCLUSION

Colposcopic terminology should be modified accordingly.

A three steps two-choices model can led to four colposcopic diagnostic categories that promise to act as independent risk stratifiers while having good reproducibility, after a learning session.

Replacing clinical protocols with risk stratification

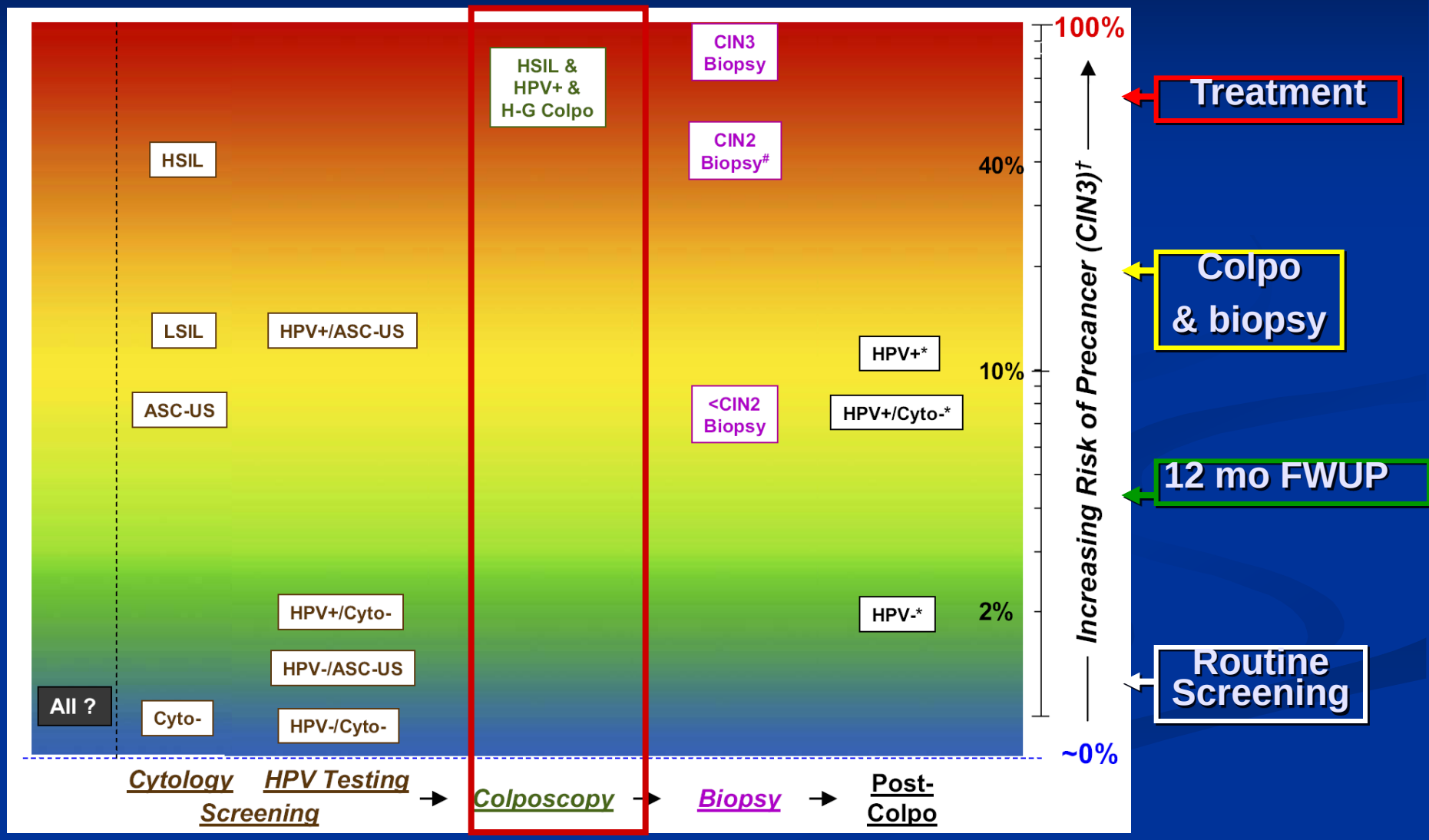

Castle PE, Sideri M, Jeronimo J, Solomon D, Schiffman M; Am J Obstet Gynecol 2007, vol 197.

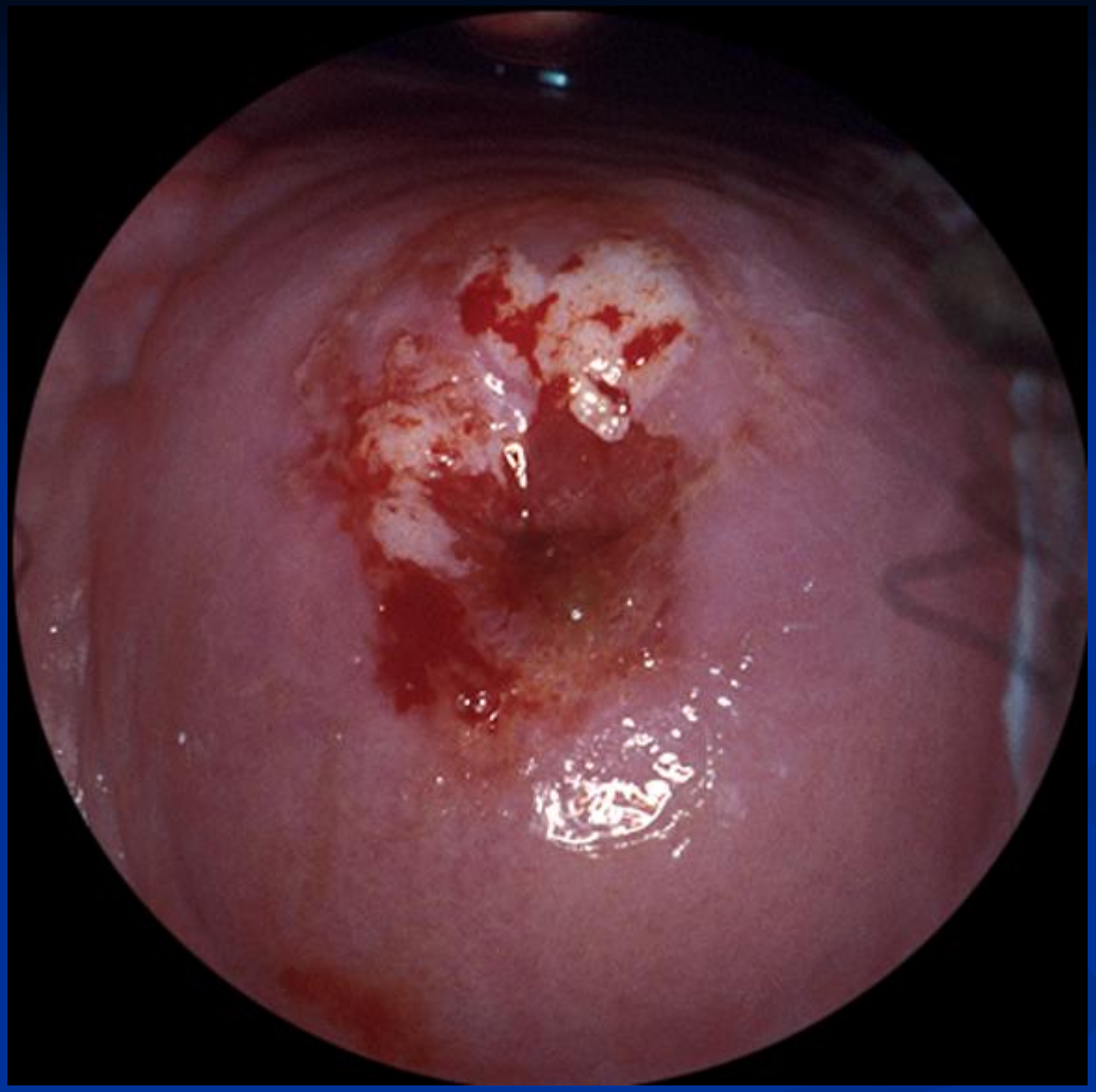

Type 1, small G2

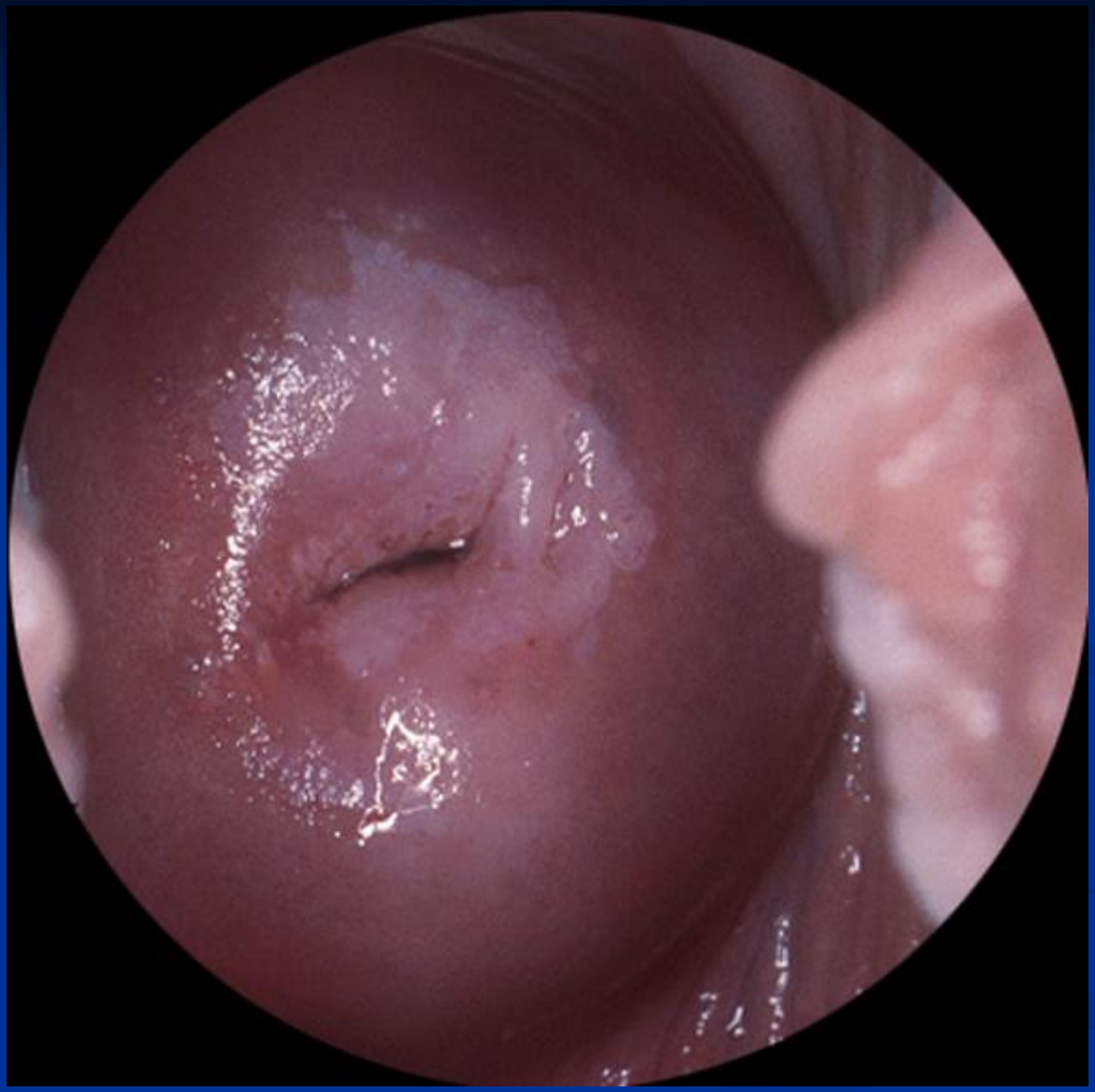

Type 2, small G2

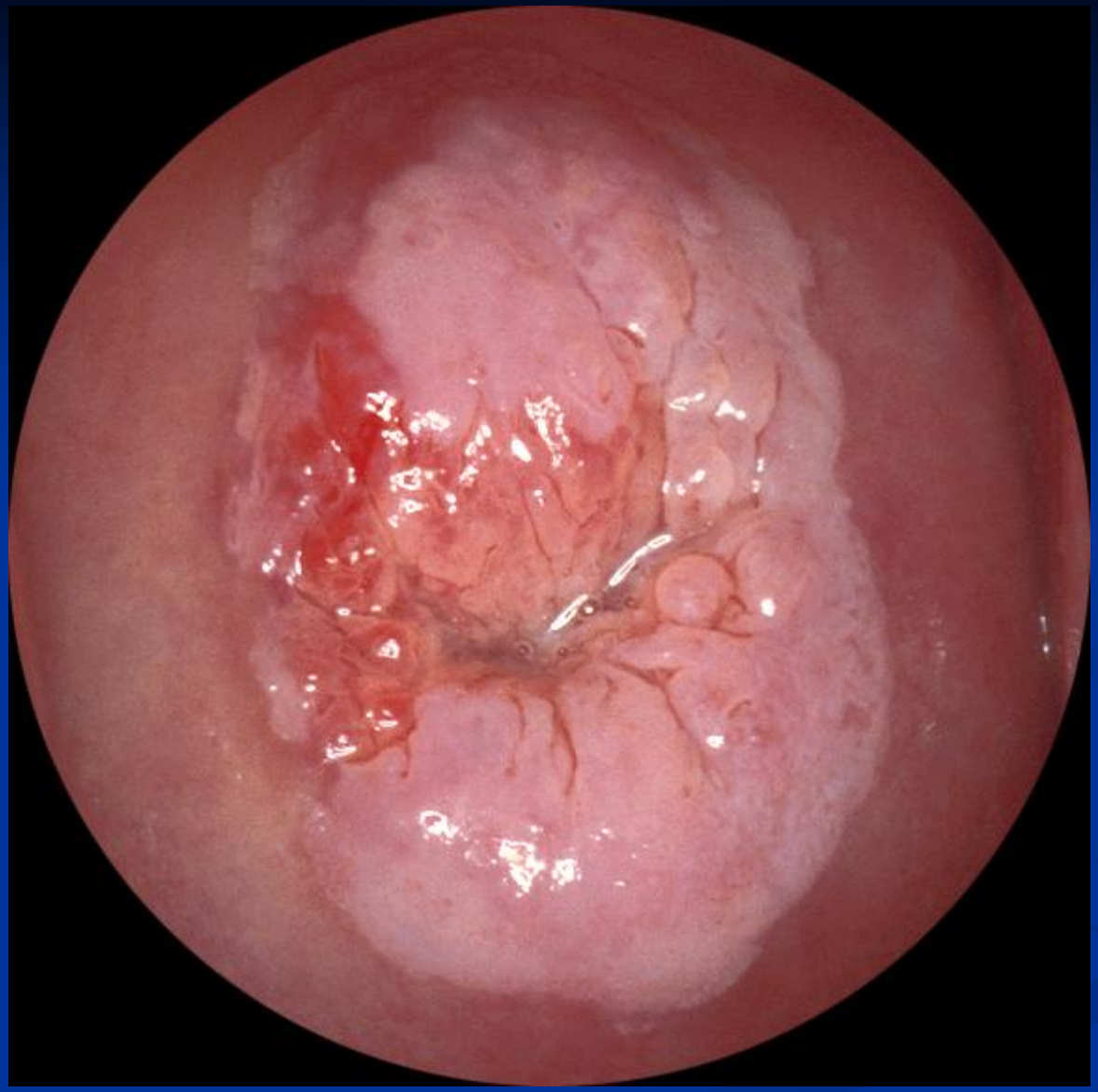

Type 2, large G2

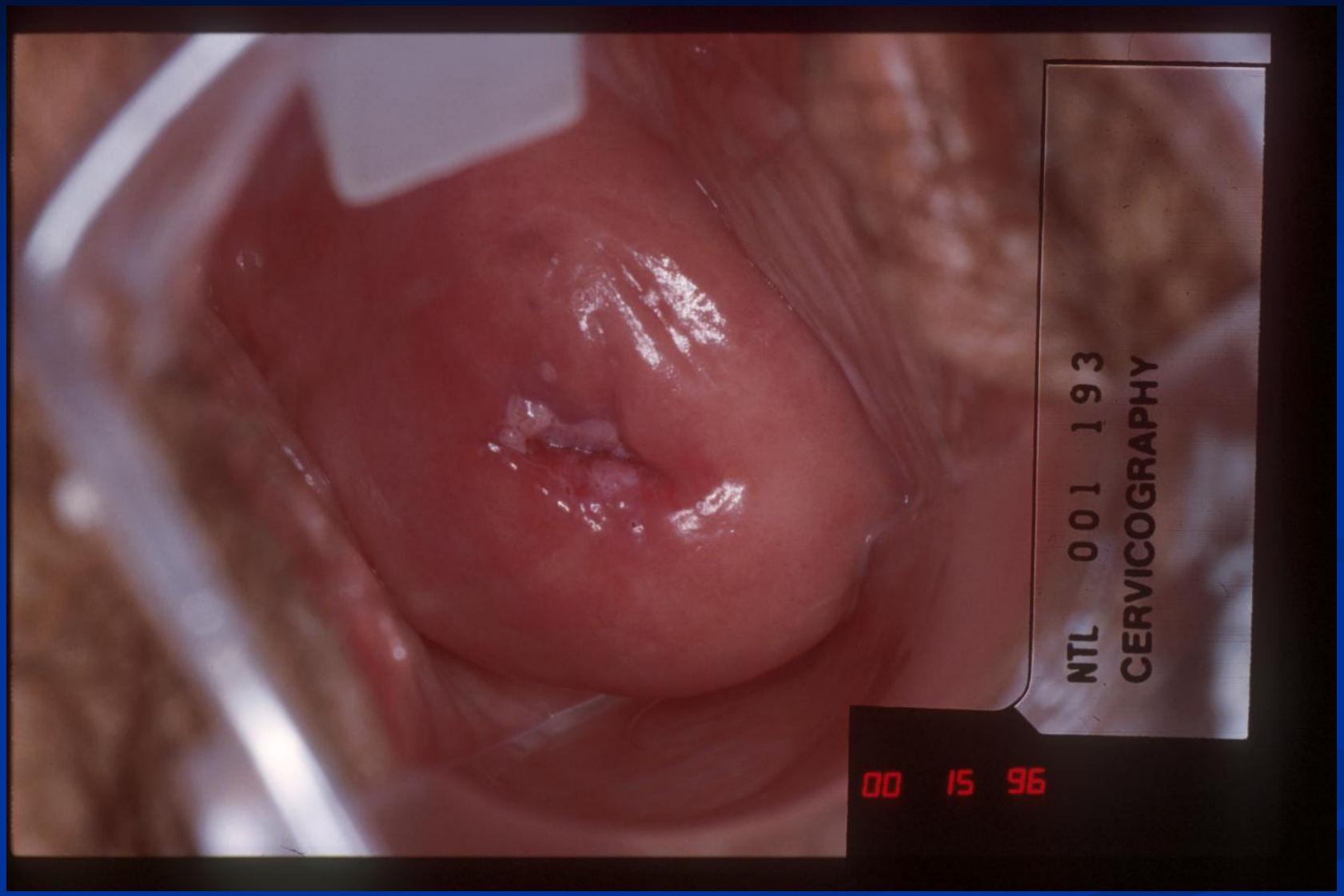

Type 3, small G2