Adenocarcinoma della cervice uterina

Problematiche in citologia a strato sottile e istologia

Giovanni Negri

Bolzano

Quali lesioni vogliamo riconoscere?

- Precursori dell’adenocarcinoma invasivo
  - La diagnosi citologica di una lesione preinvasiva cervicale deve riferirsi a una lesione dai criteri istologici e potenzialitá biologica definiti
  - La diagnosi citologica di una lesione cervicale deve essere riproducibile
  - La diagnosi citologica di lesione endocervicale deve comprendere lesioni biologicamente rilevanti

Quali lesioni vorremmo riconoscere?

- Adenocarcinoma
- Adenocarcinoma microinvasivo
- Adenocarcinoma in situ
- Precursori dell’AIS
- Alterazioni non neoplastiche

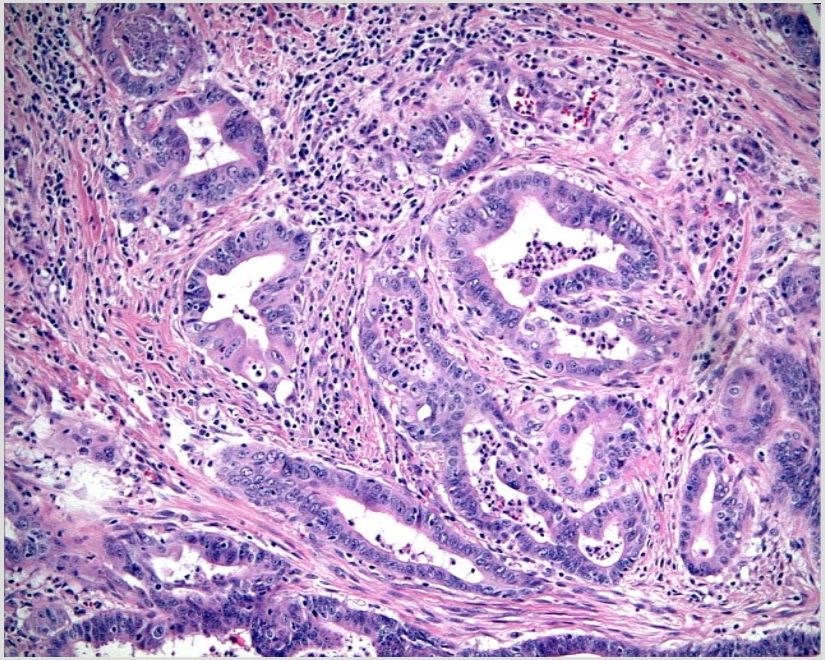

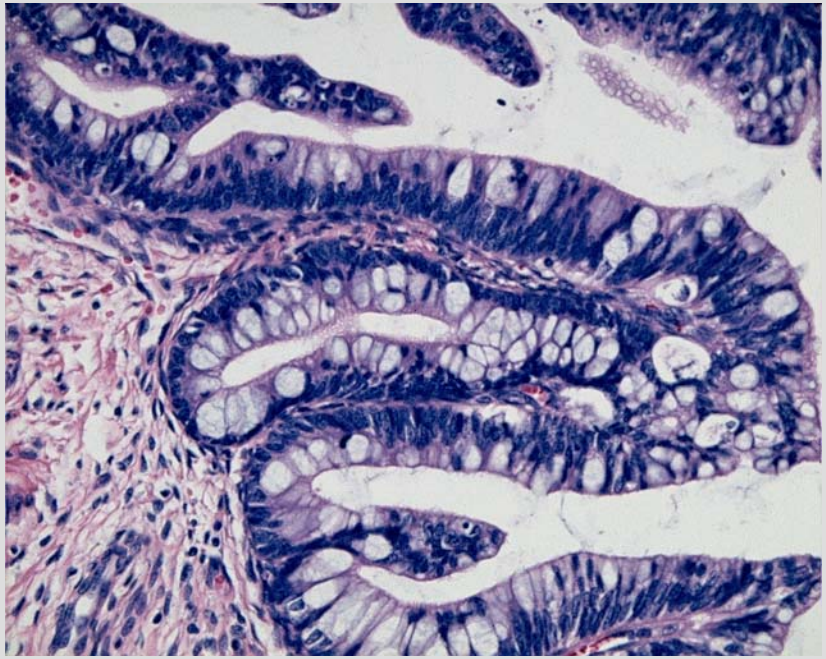

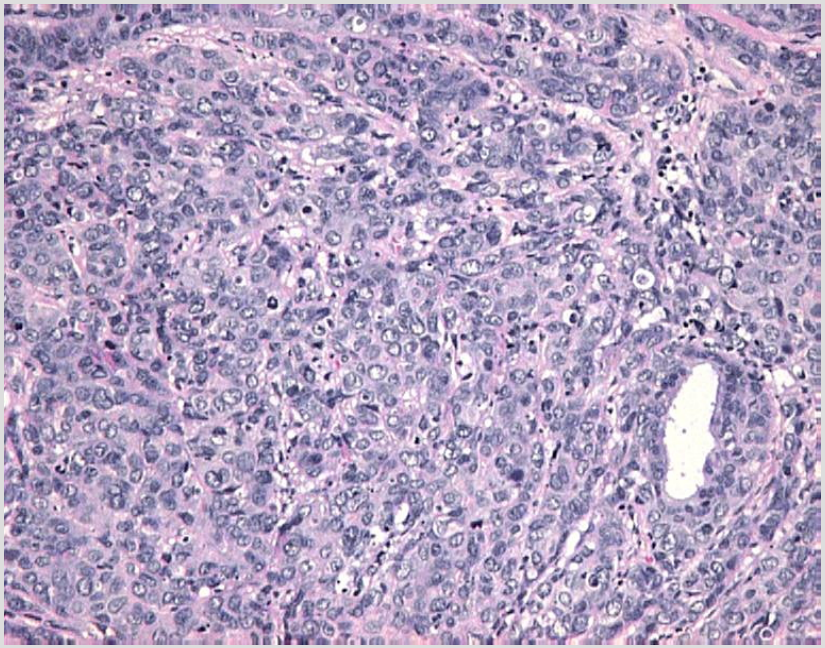

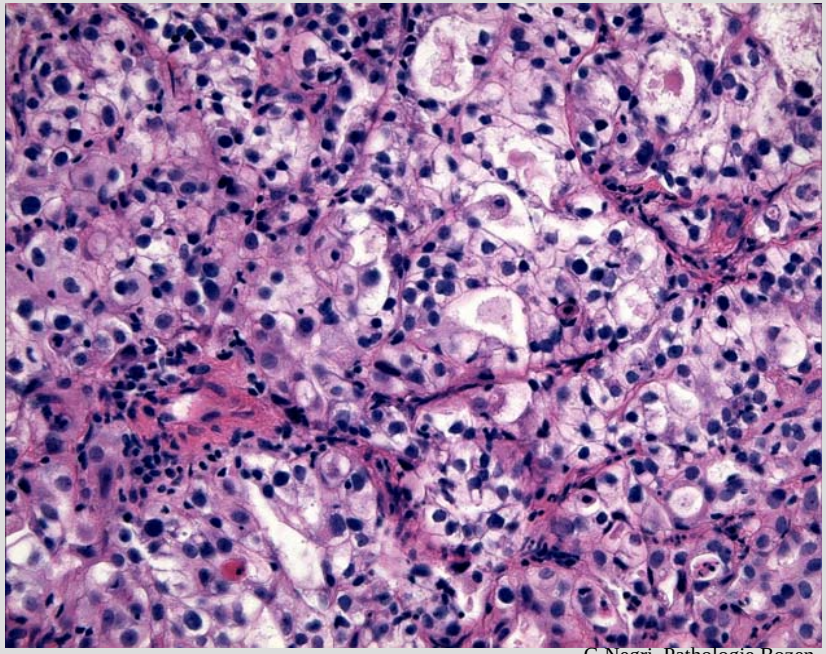

G.Negri, Pathologie Bozen

AGC+ nel pap-test precedente la diagnosi istologica di AIS

- Cullimore et al. (1992): 53%
- Andersen et al (1989): 50%
- Mitchell et al. (1994) 56%

- Lee et al (1997): 55% of negative smears were retrospectively diagnosed as abnormal
- Ruba et al (2004): 35,1% sampling errors vs 10,4% screenig/diagnostic errors (AIS)

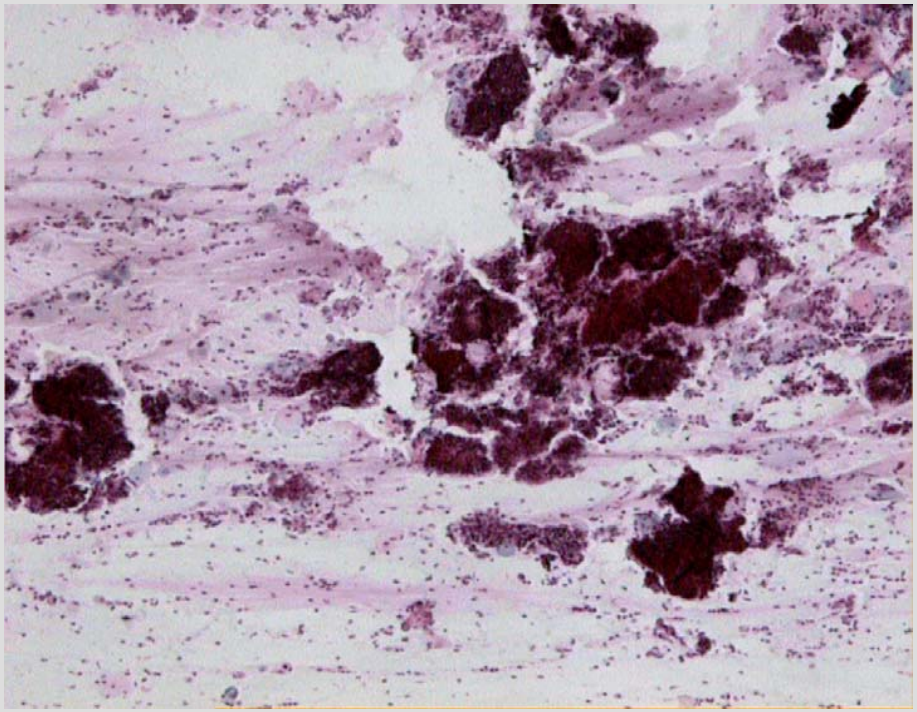

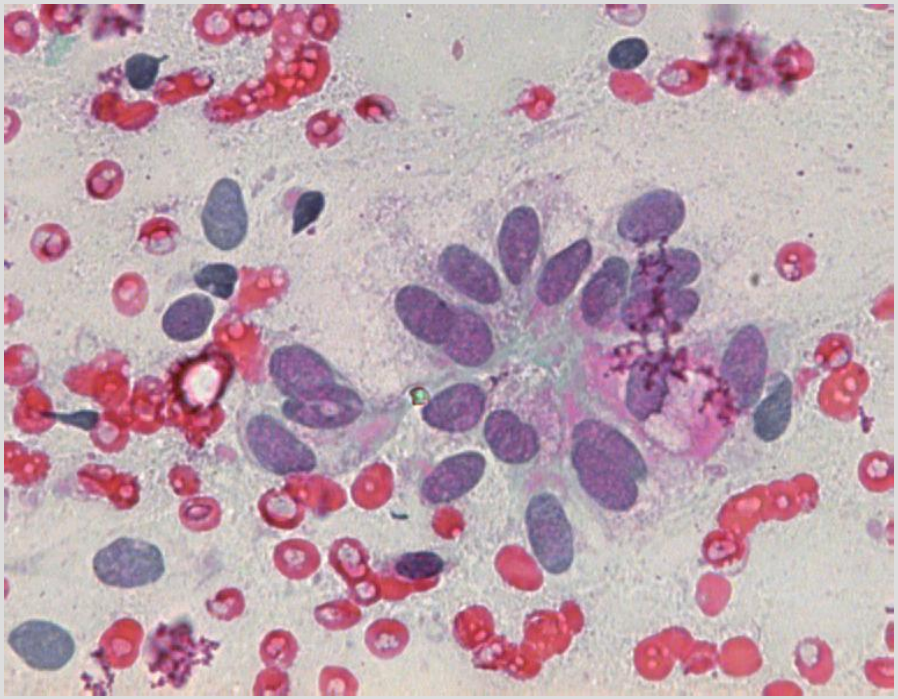

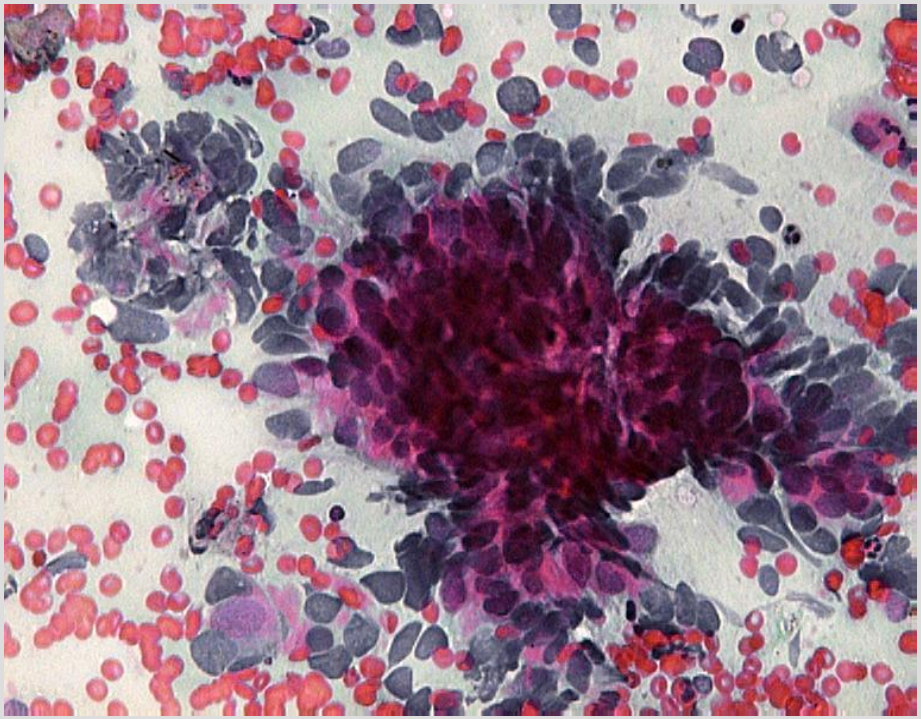

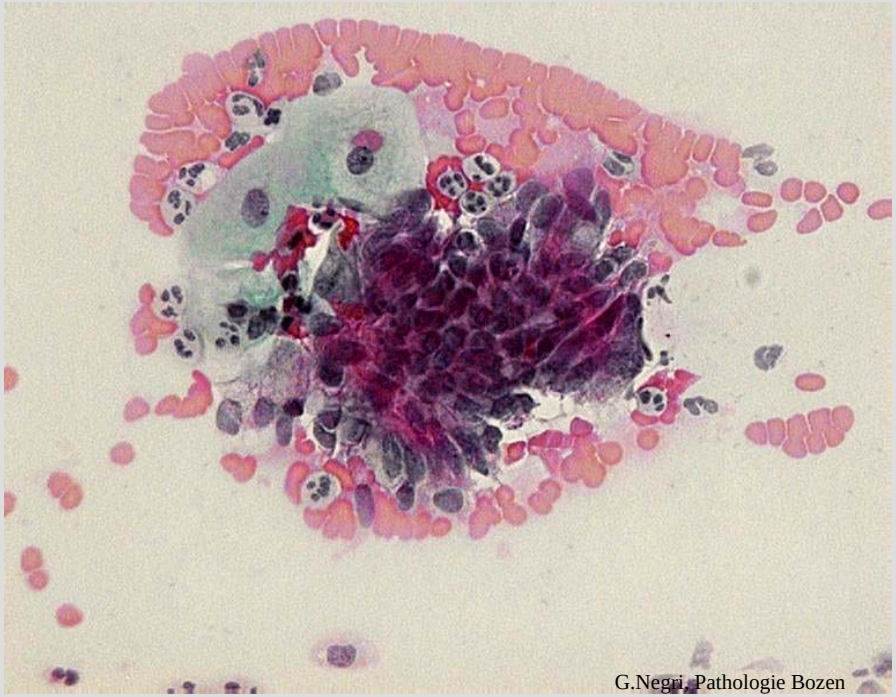

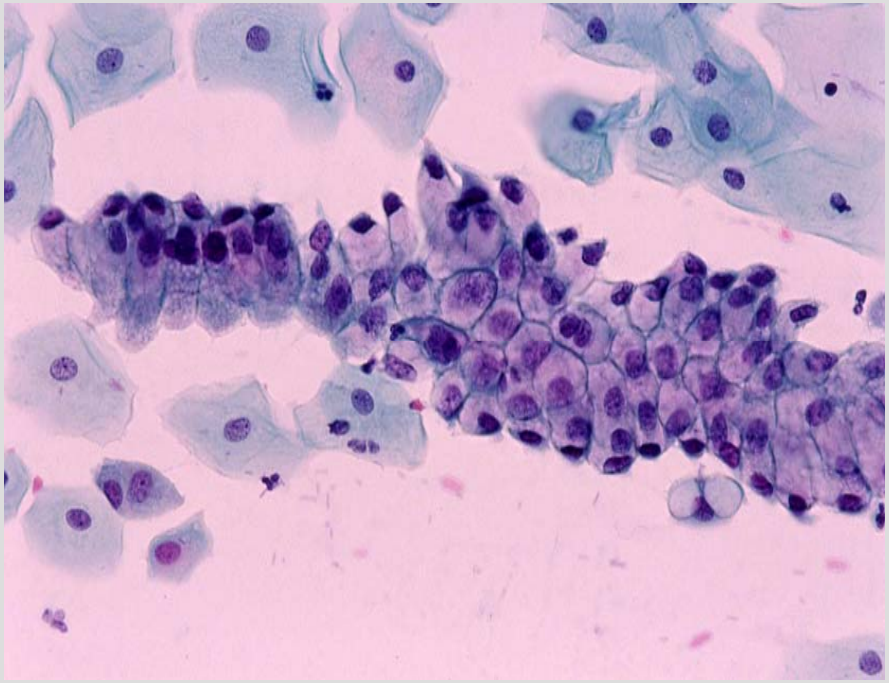

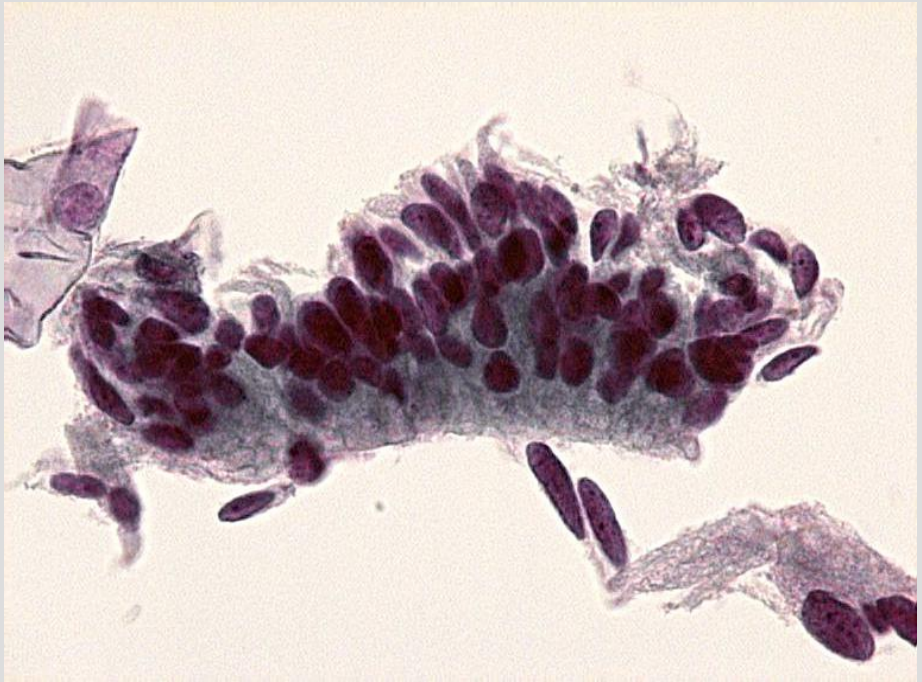

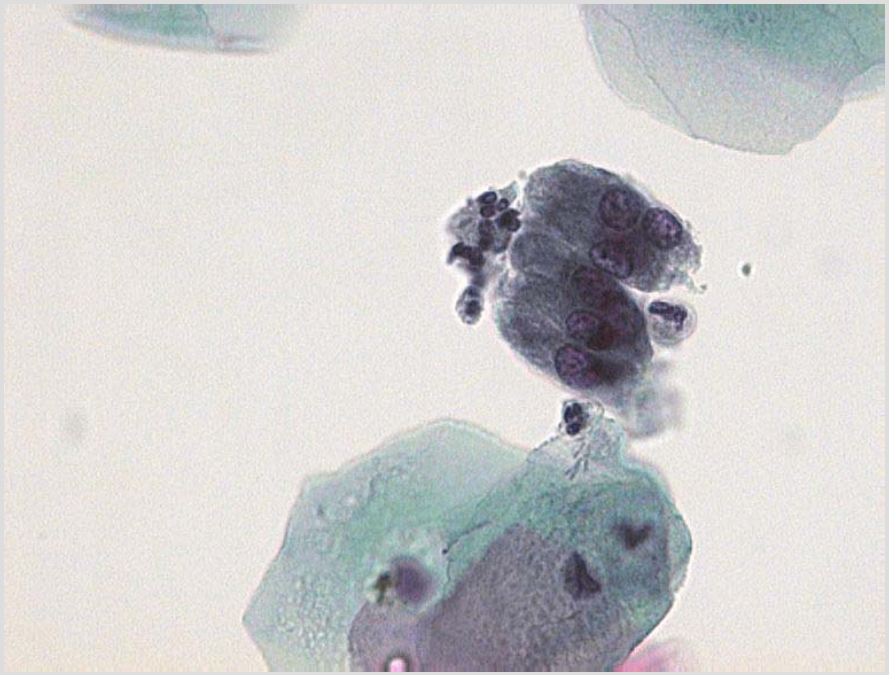

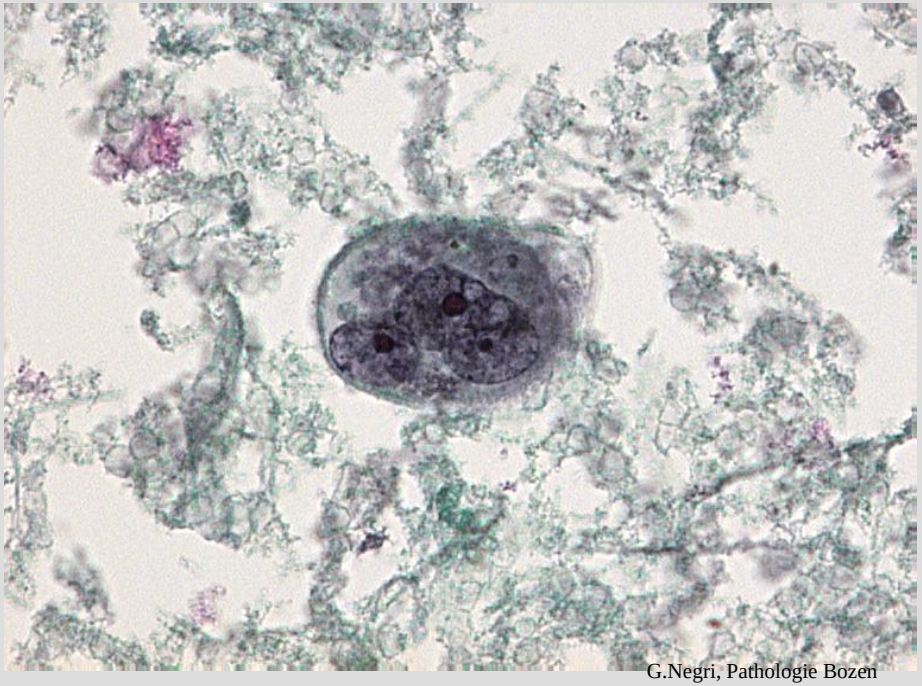

G.Negri, Pathologie Bozen

LBC vs. Pap-test convenzionale

- Ashfaq et al. (Acta Cytol 1999): “the ThinPrep method provides more accurate diagnoses of glandular disease, with an increase in both sensitivity and specificity for glandular lesions”
- Roberts et al. (Acta Cytol 1999): “AIS was accurately predicted by PS in 67% and SSTP in 47% (Split sample)
- Schorge et al, (Cancer 2002): “The sensitivity of an adenocarcinoma/AGUS ThinPrep smear in detecting cervical adenocarcinoma was 87,1% compared with 55,5% in the control group”

Adenocarcinoma cervicale in-situ

- Endocervicali con formazione di palizzate di nuclei ipercromici, pseudostratificati
- Feathering, rosette
- Nucleoli non prominenti
- Fondo pulito
- DD: metaplasia tubarica, HSIL, CEC reattive
- DD con artefatti da brushing non esiste

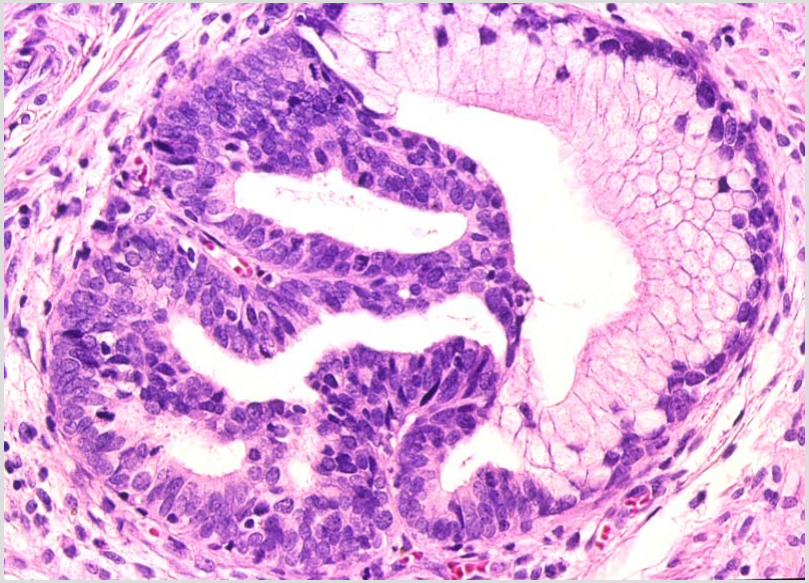

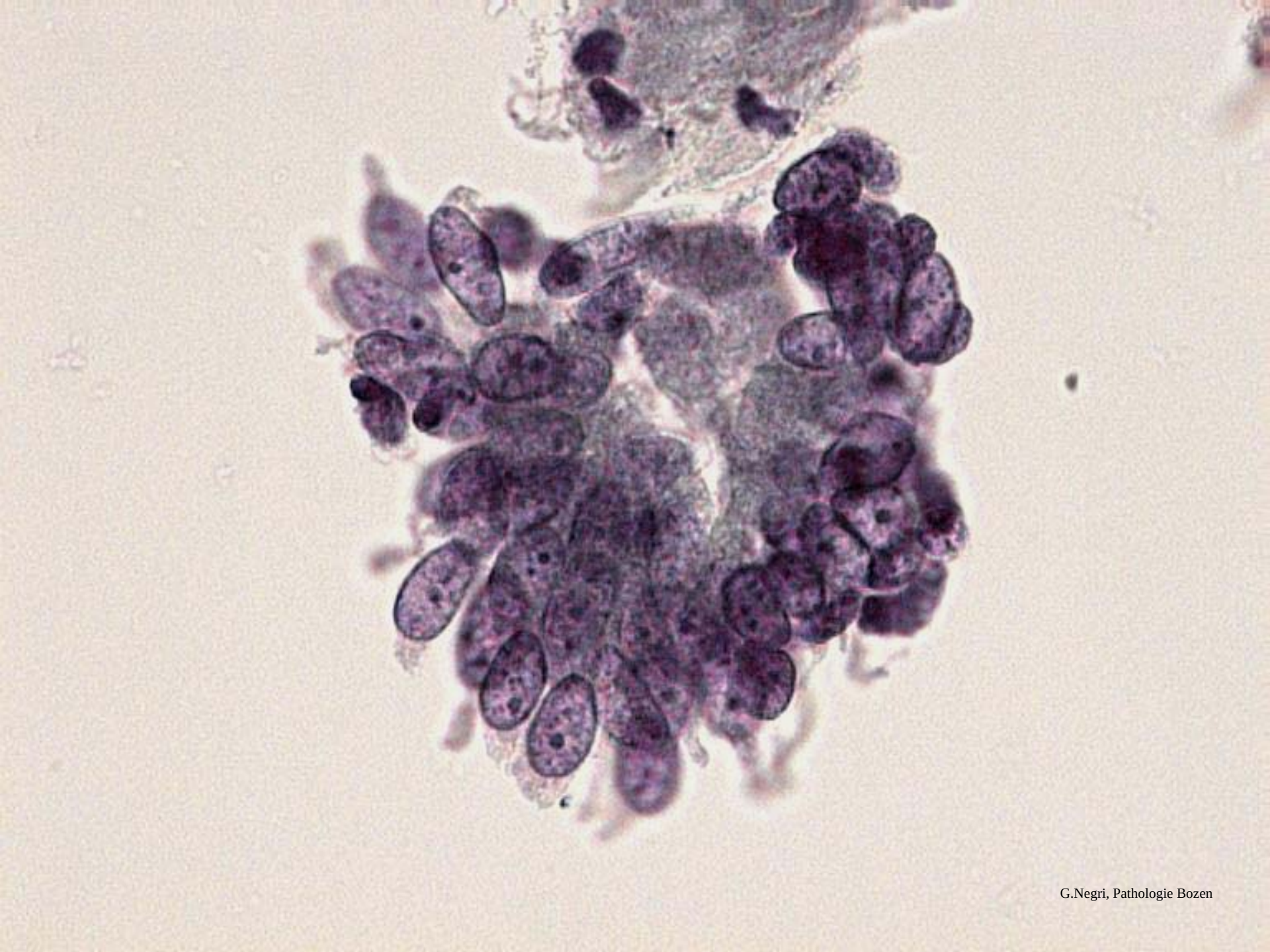

G.Negri, Pathologie Bozen

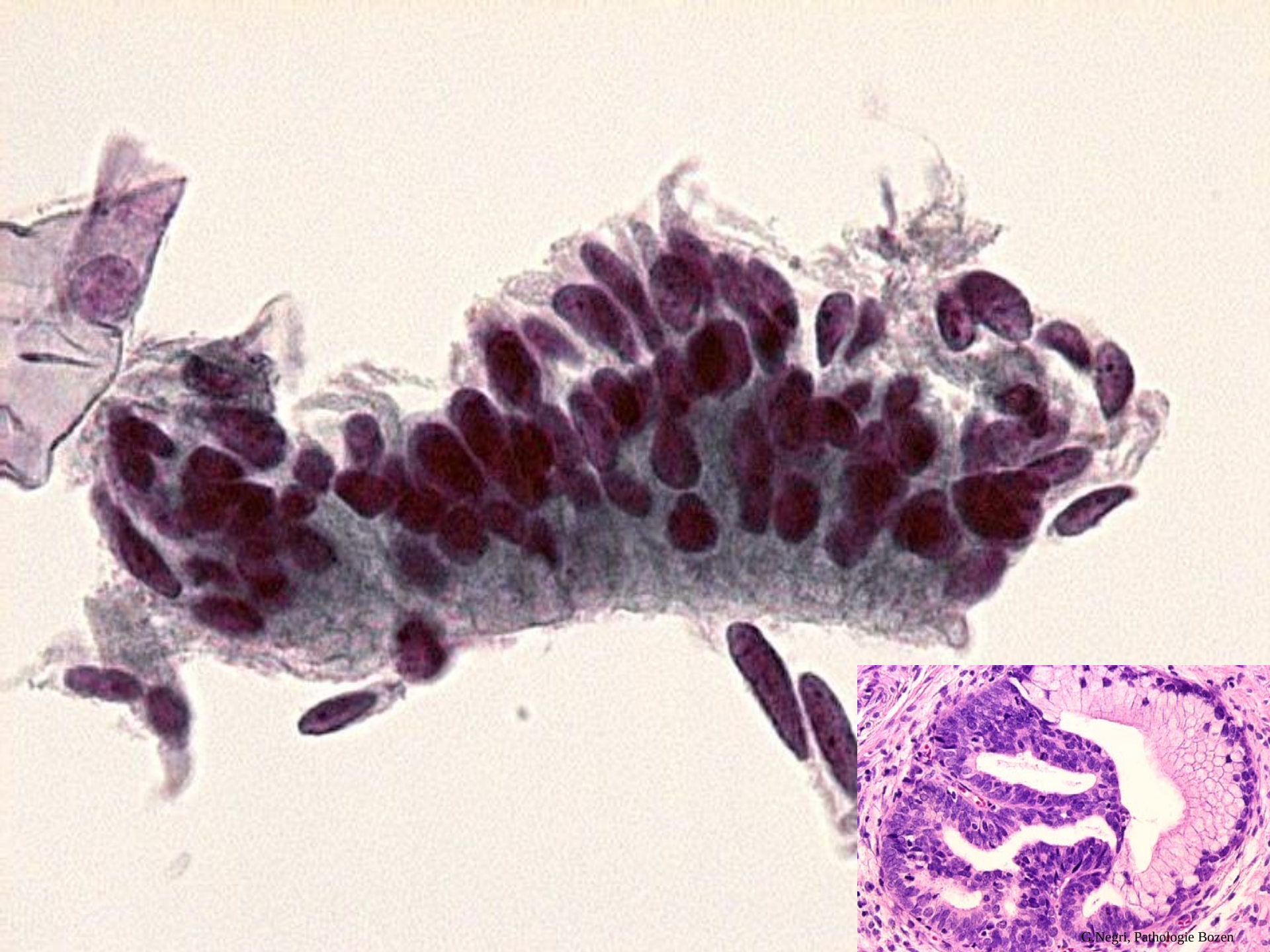
G.Negri, Pathologie Bozen

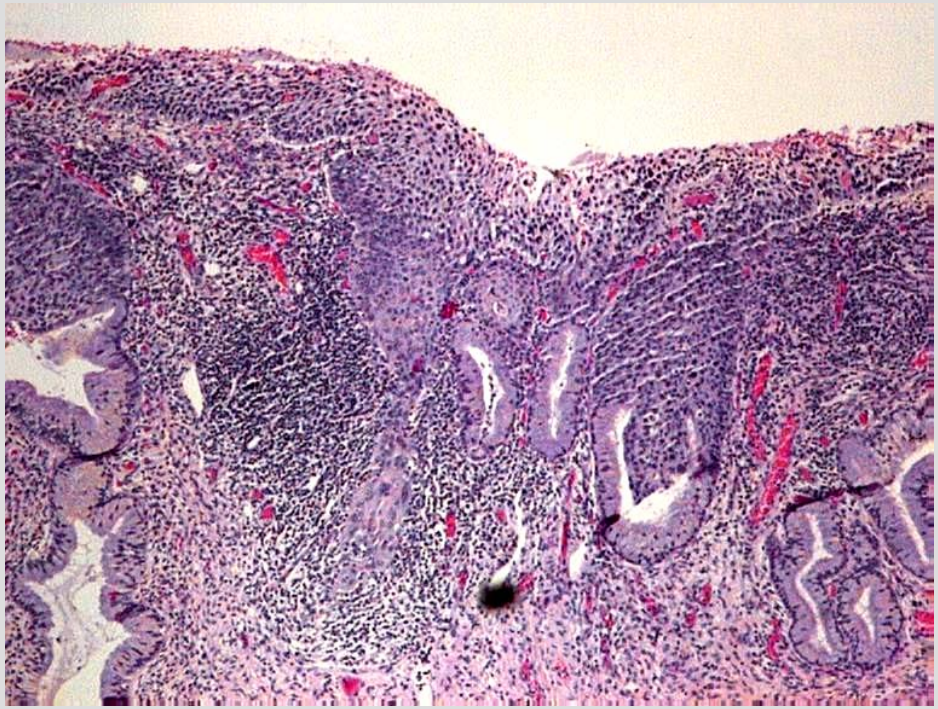

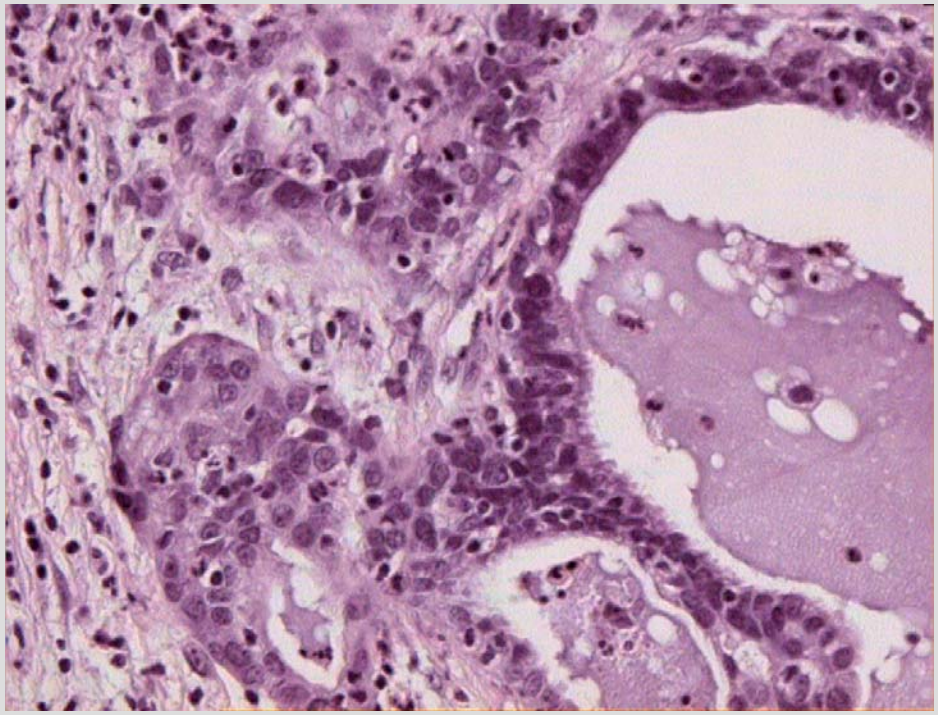

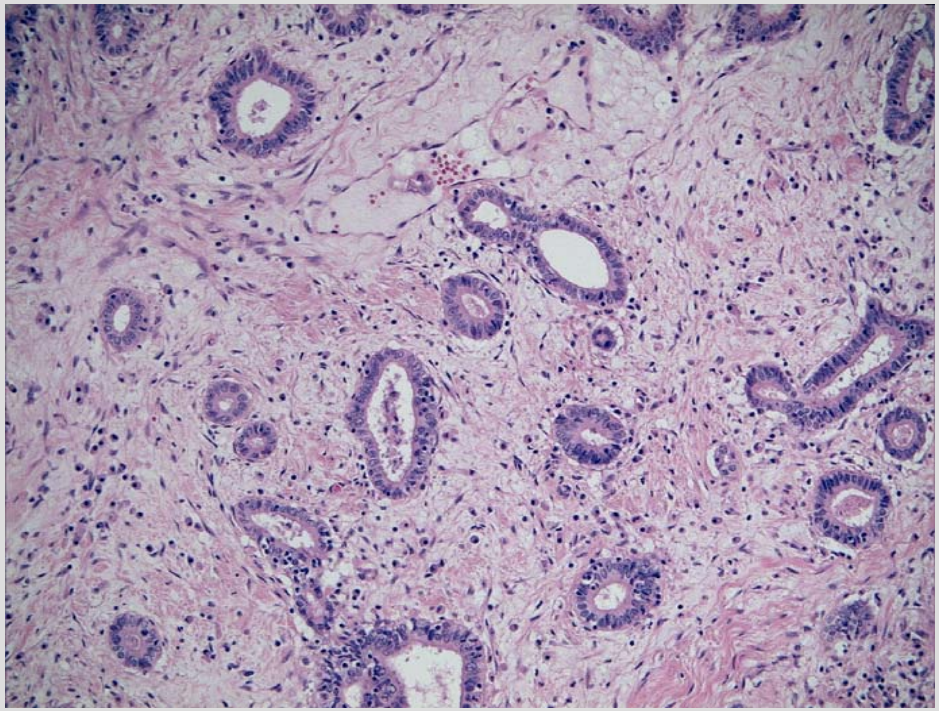

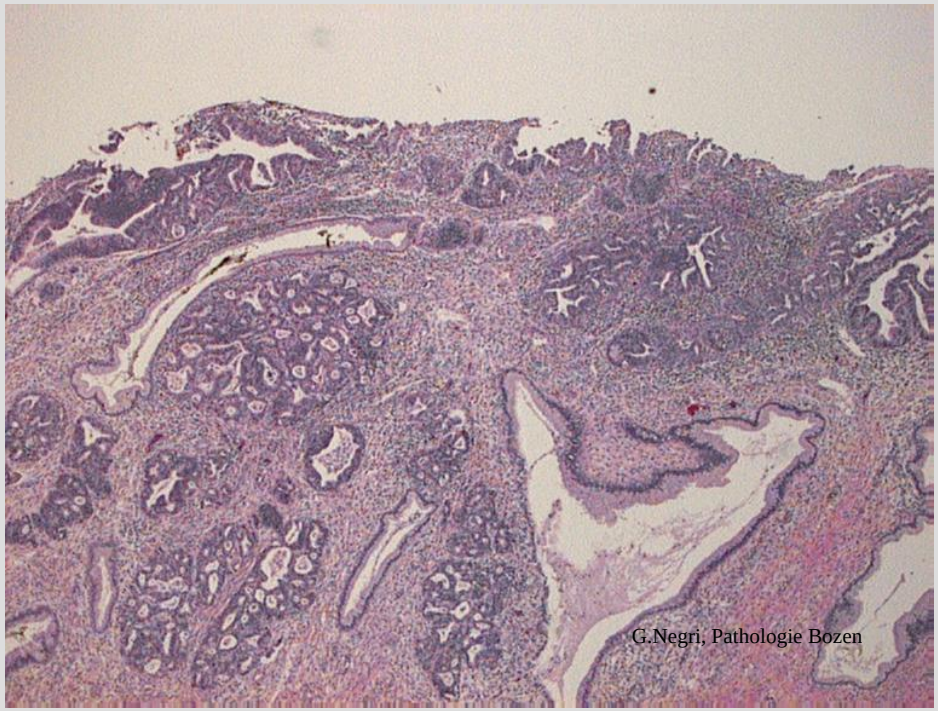
G.Negri, Pathologie Bozen

Adenocarcinoma microinvasivo

- Östör 2000: “In about 20% of cases it is impossible to (hisologically) distinguish AIS from early invasive adenocarcinoma”
- WHO 2003: “glandular neoplasm in which the extent of stromal infiltration is so minimal thath the risk of local lymph node metastasis is negligible”
  - < 5 mm?, < 3 mm?, < 1 mm?

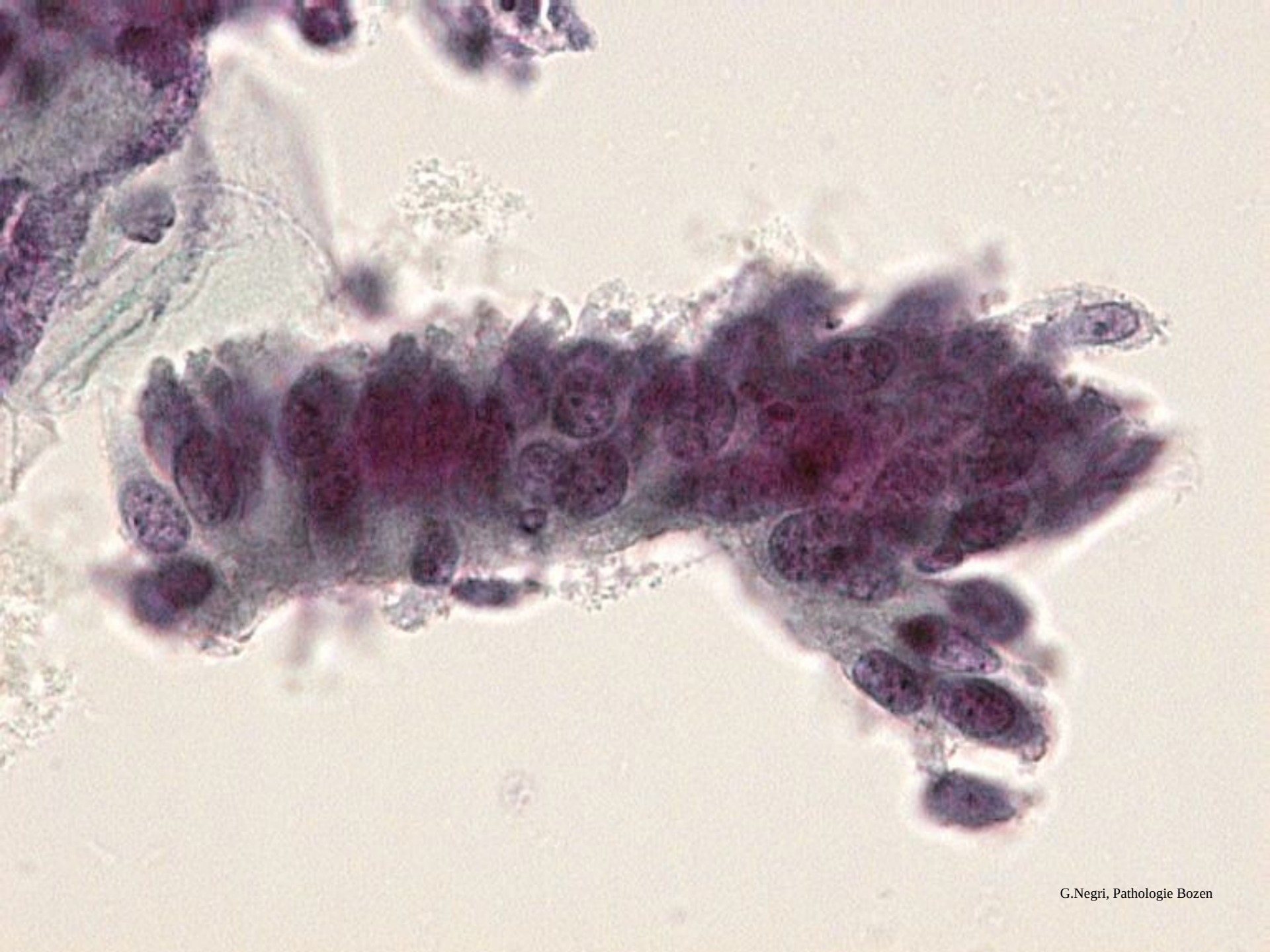

G.Negri, Pathologie Bozen

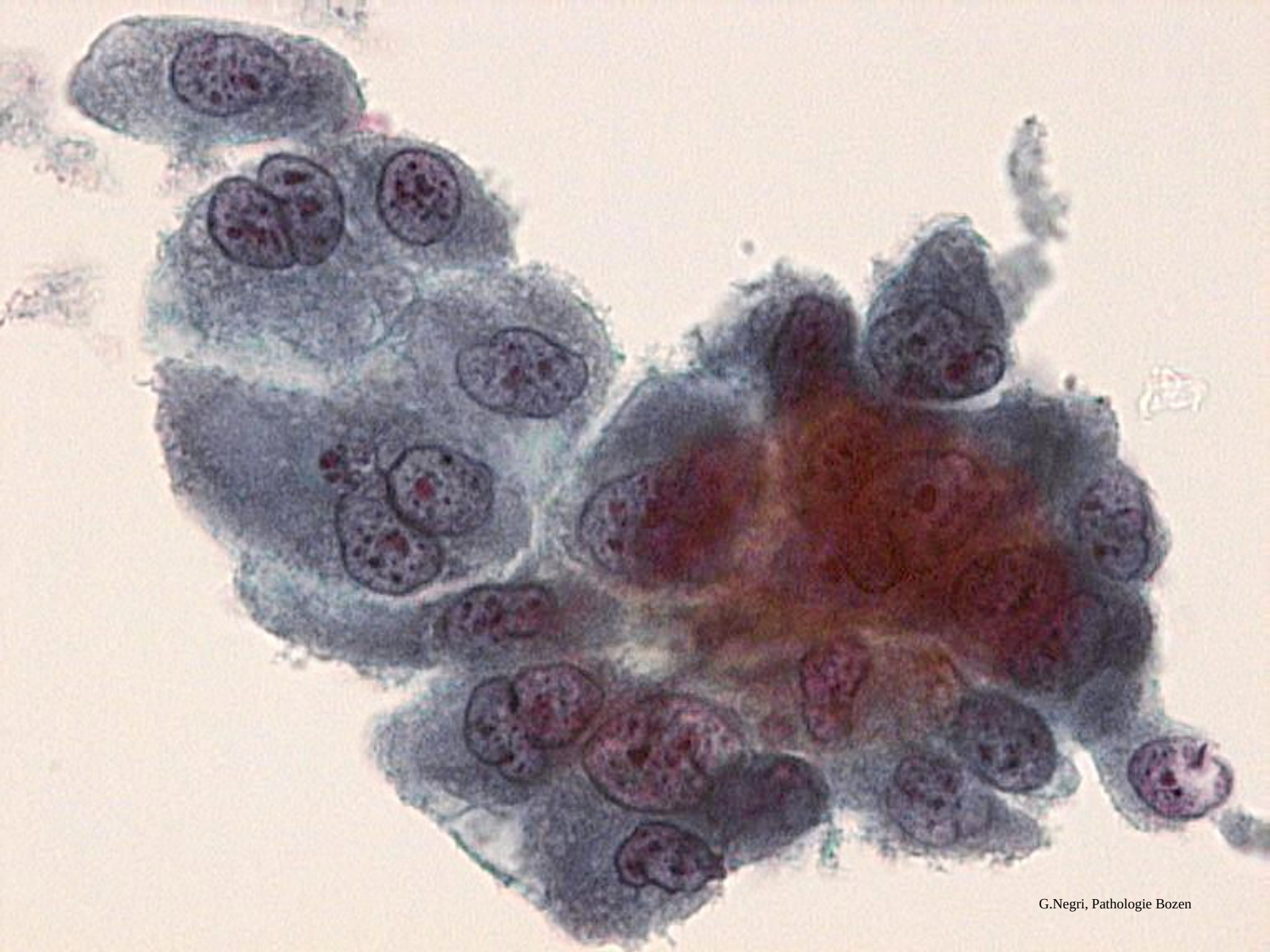

G.Negri, Pathologie Bozen

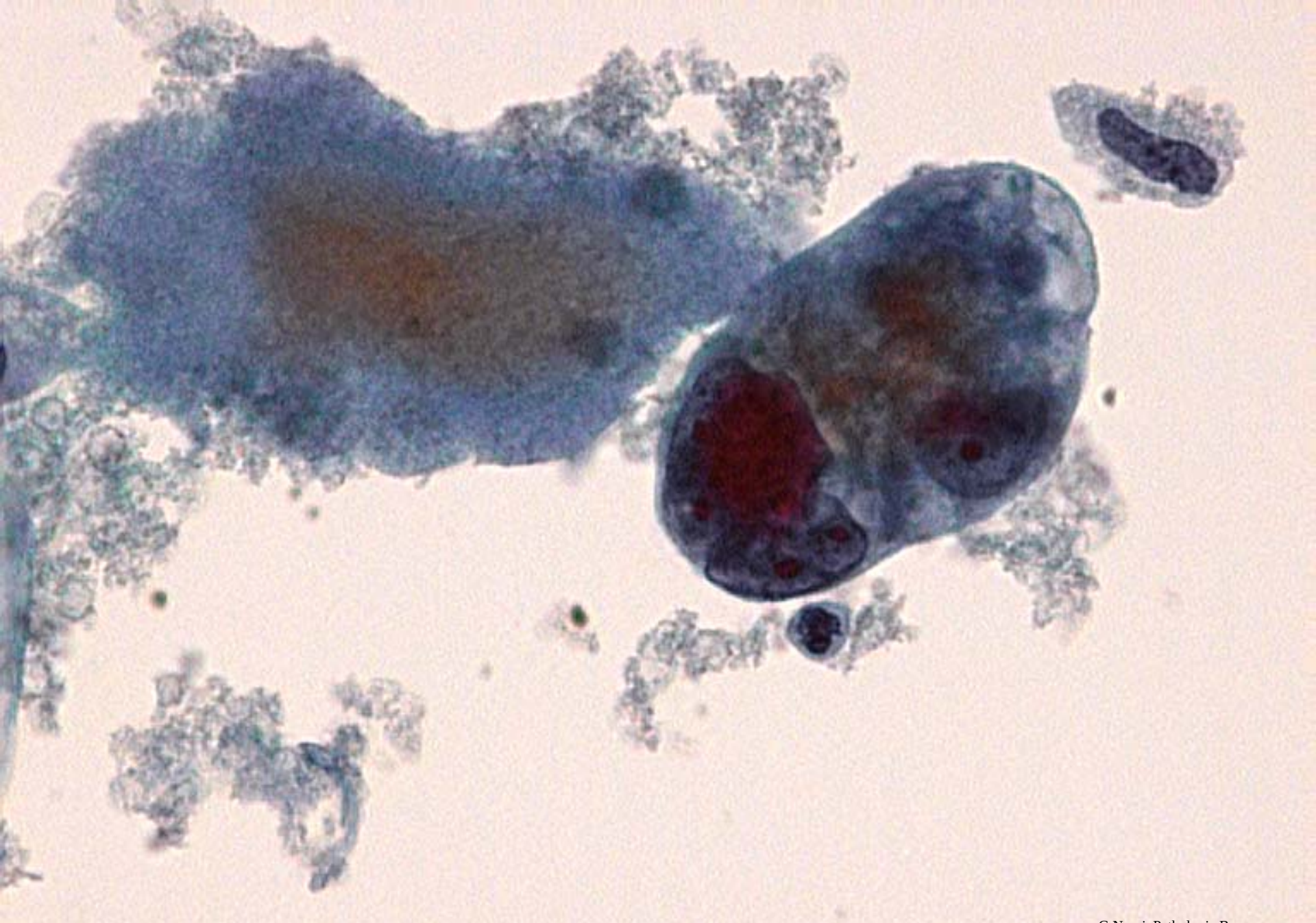

G.Negri, Pathologie Bozen

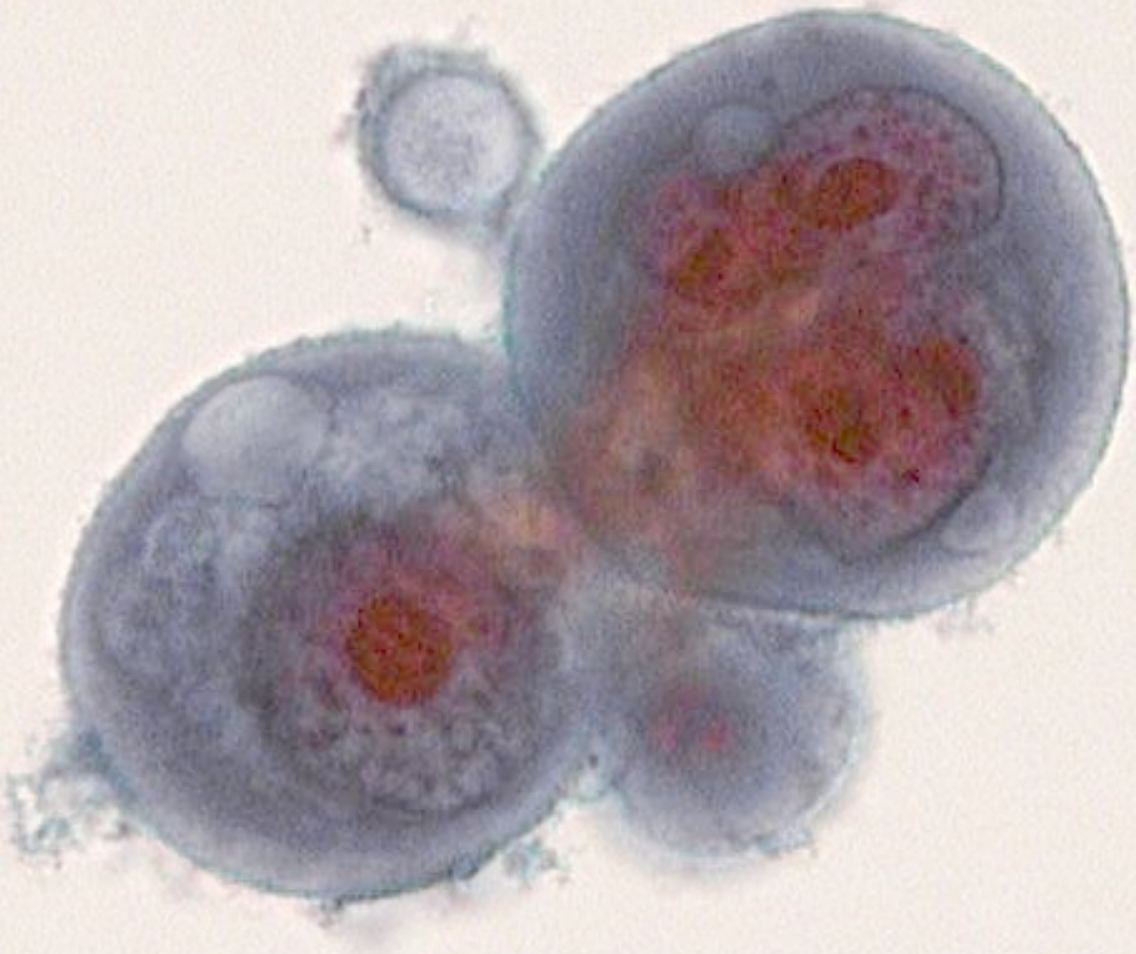

G.Negri, Pathologie Bozen

Endocervicali reattive

- Conservazione della struttura ad alveare
- Micronucleoli evidenti, affollamento nucleare
- <u>Nuclei rotondeggianti, non vere palizzate con stratificazione nucleare</u>

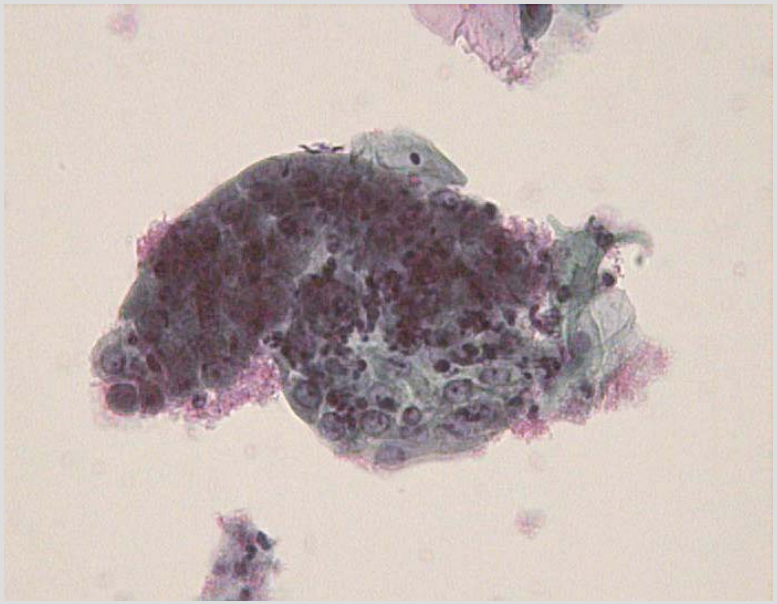

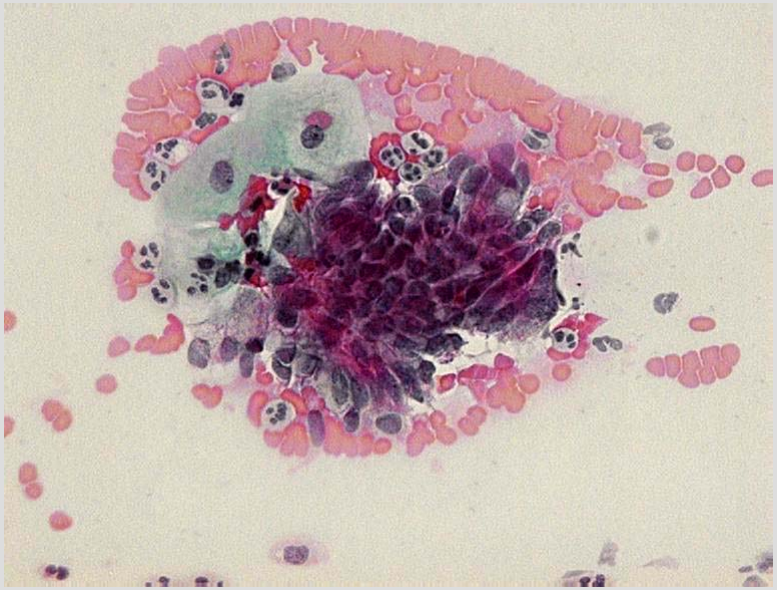

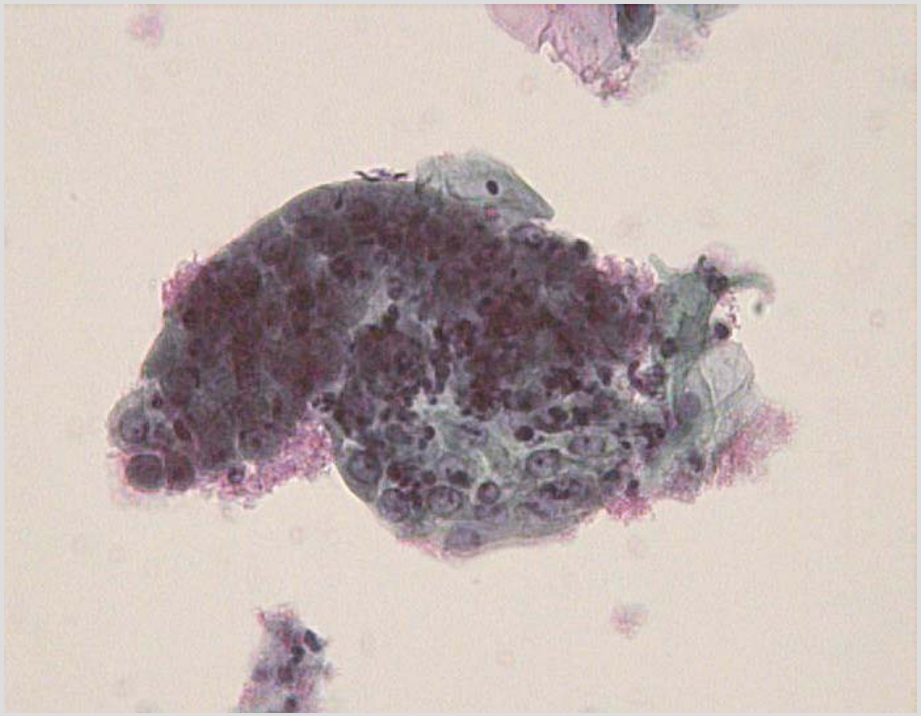

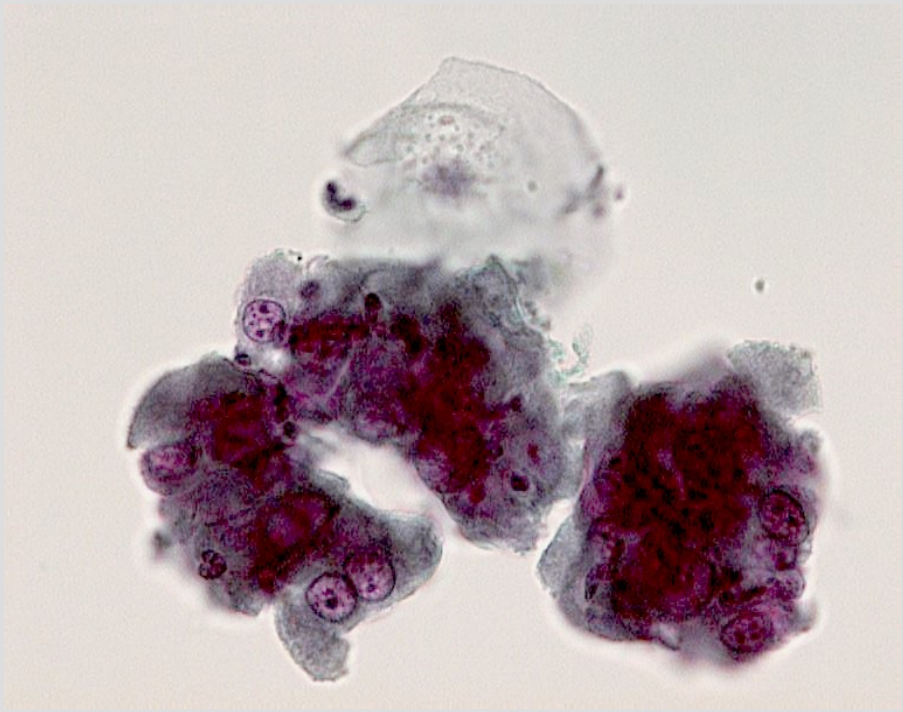

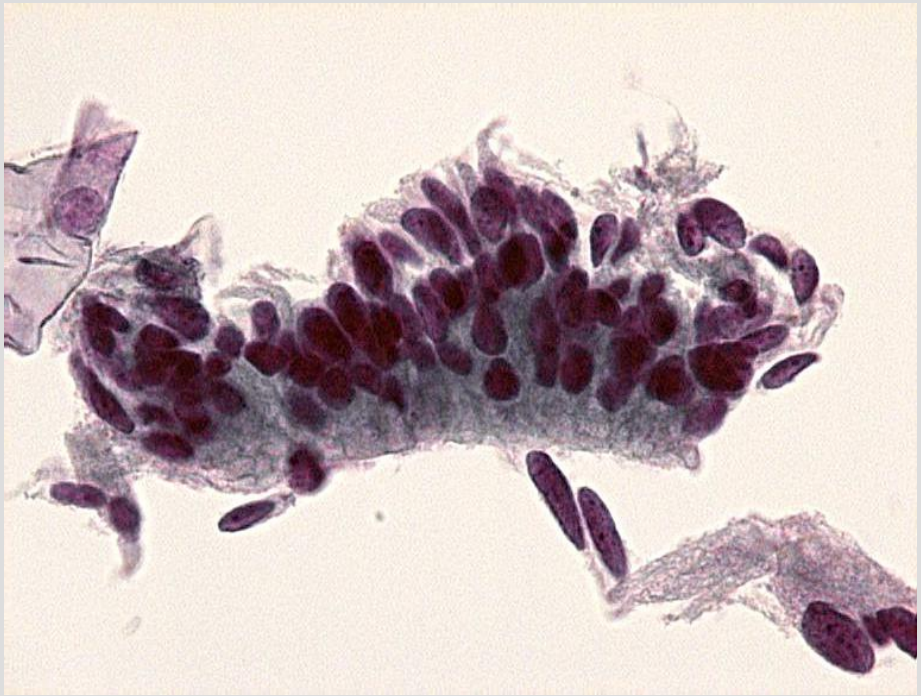

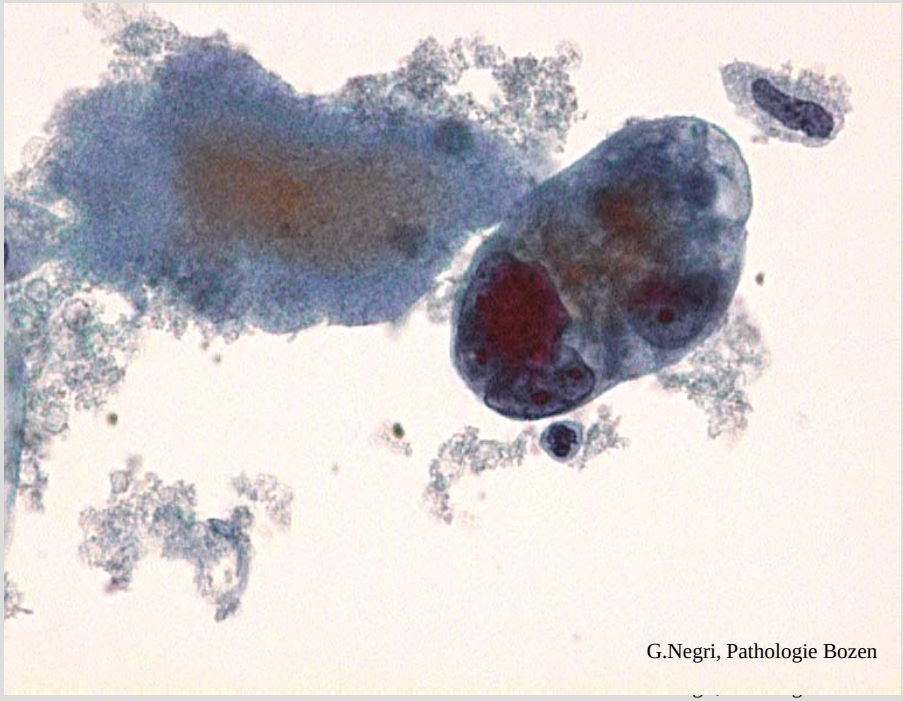
G.Negri, Pathologie Bozen

Follow-up citologico di ASC-H/AGC: LBC vs. Convenzionale. (*2003*)

	convenzionale (n=114)	% soddisfacenti convenzionale	ThinPrep (n=100)	% soddisfacenti ThinPrep
WNL	45		42	
SIL	10		37	
AIS	1		3	
Carcinoma	2		0	
Totale diagnosi chiare	**58 (50.9%)**	**50.0%**	**82 (82.0%)**	**84.2%**
ASC/AGC	50		18	
inadeguato	6		0	
Tot. diagnosi non chiare	**56 (49.1%)**	**37.5%**	**18 (18.0%)**	**72.2%**

Cancer Cytopathology 2003

Look-alikes: epitelio ghiandolare

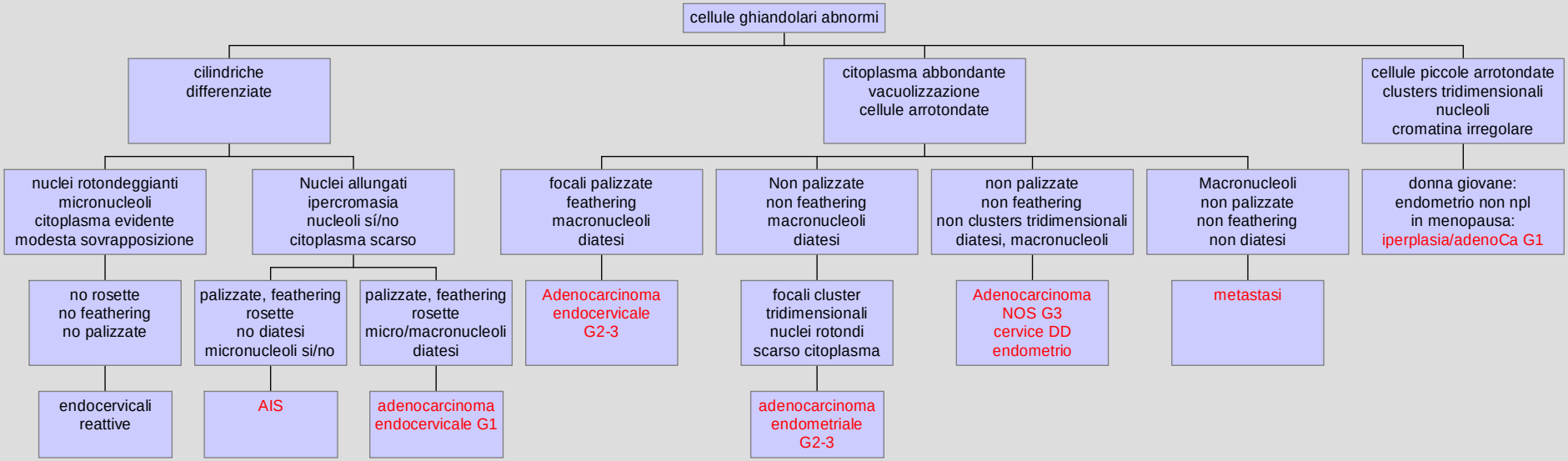

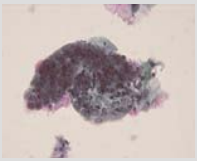

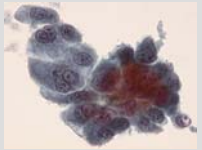
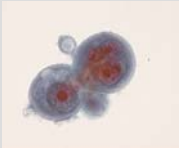
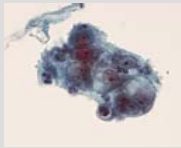
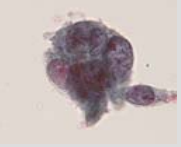
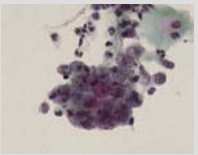
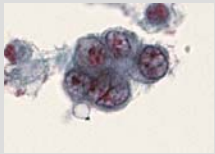

Minimal deviation adenocarcinoma

- WHO 2003: “adenocarcinoma in which most of the glands are impossible to distinguish from normal”
- La diagnosi puó essere impossibile su materiale bioptico (Young e Clement 2002)
- Concordanza diagnostica in istologia 23% (Tsuda, 2003)
- Granter e Lee 1996: 6/7 casi con pap precedente negativo. Alla revisione: 3 casi con cellule abnormi “classiche”

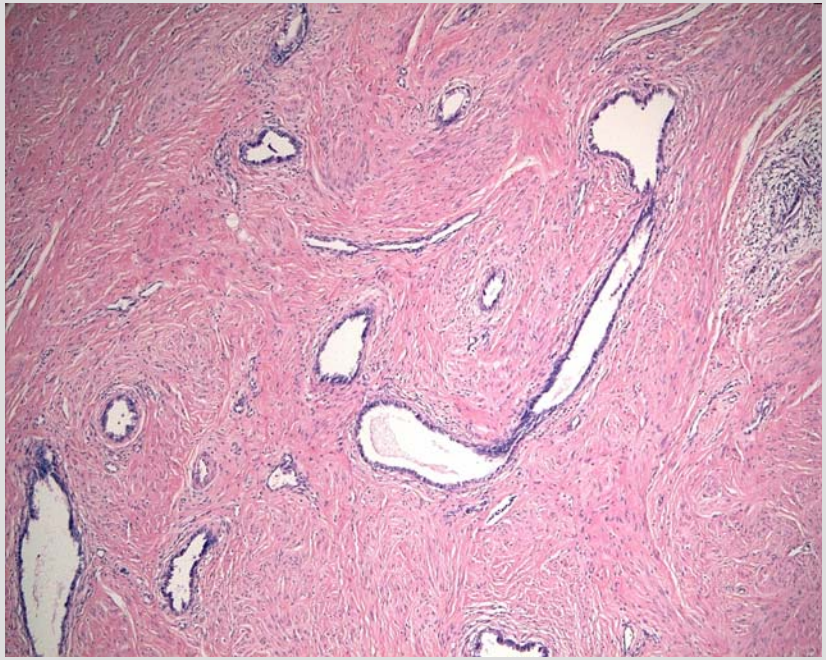

Minimal deviation adenocarcinoma

- P16 positivo in 30% dei MDA vs. 93% dei ADCA convenzionali (Mikami et al 2004)
- HPV assente in 11/11 casi (Pirog et al 2000)
- Alcian-Pas (mucine neutre in rosso vs. violetto in mucine acide di CEC normali)
- Immunoistochimica con HIK1083 (mucine di tipo gastrico)

Esistono precursori dell’adenocarcinoma in situ e se sí la loro diagnosi é riproducibile?

- Glandular atypia
- Glandular dysplasia
- CGIN (cervical glandular intraepithelial neoplasia)
  - Low grade
  - High grade (=AIS)

WHO 2003

- Glandular Dysplasia (HG-CGIN): glandular lesion with significant nuclear abnormalities that are more striking than those in glandular atypia but fall short of the criteria for AIS.
- The concept that GD forms a biological spectrum of CGIN remains unproven

WHO 2003

- Glandular atypia (LG- CGIN): alteration which does not fulfil the criteria for glandular dysplasia or AIS and which may be associated with inflammation or irradiation.

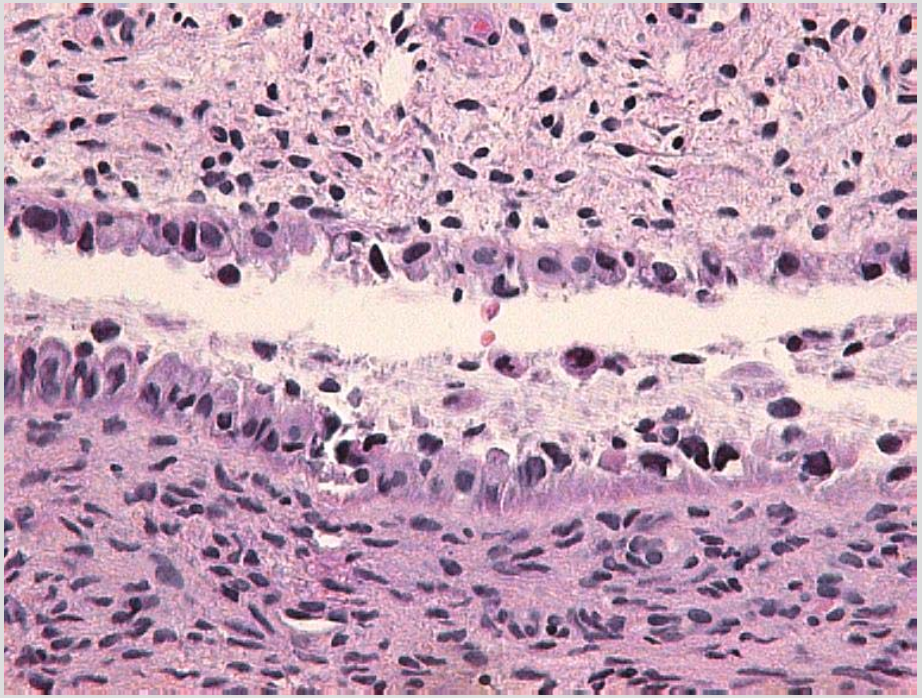

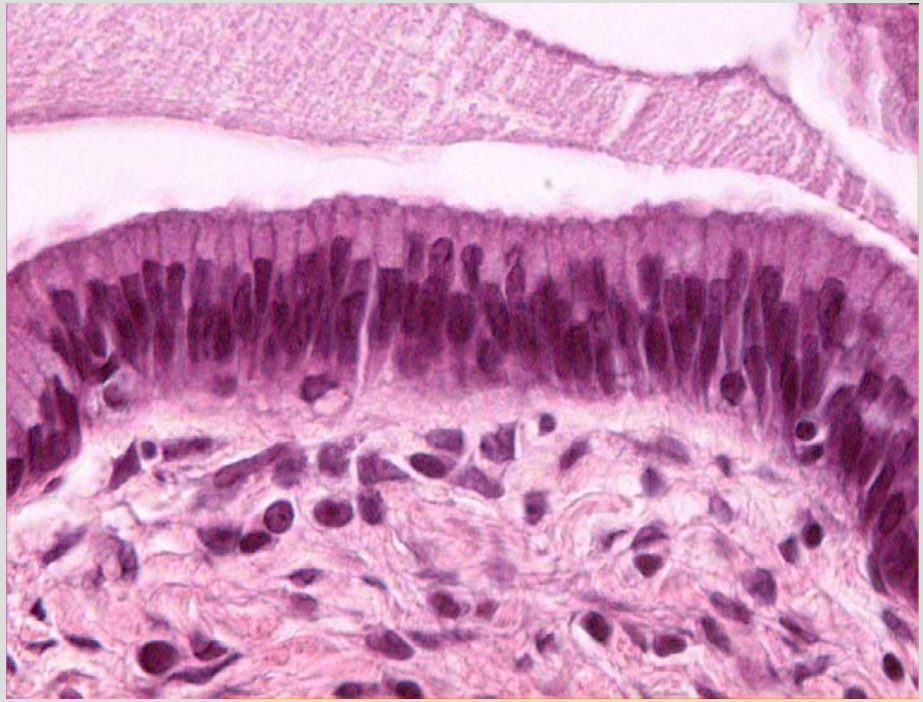

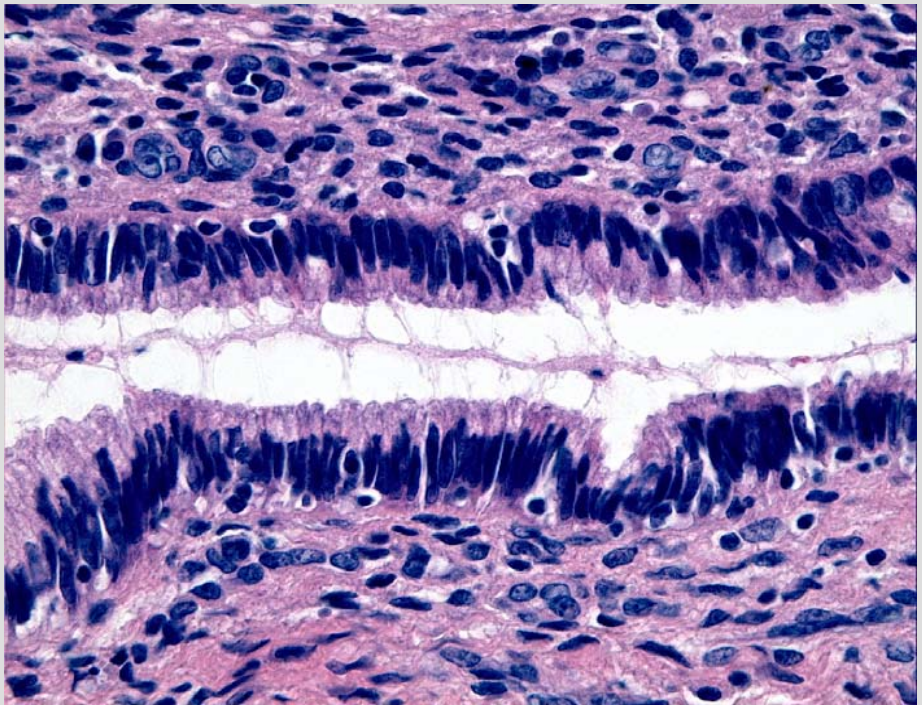

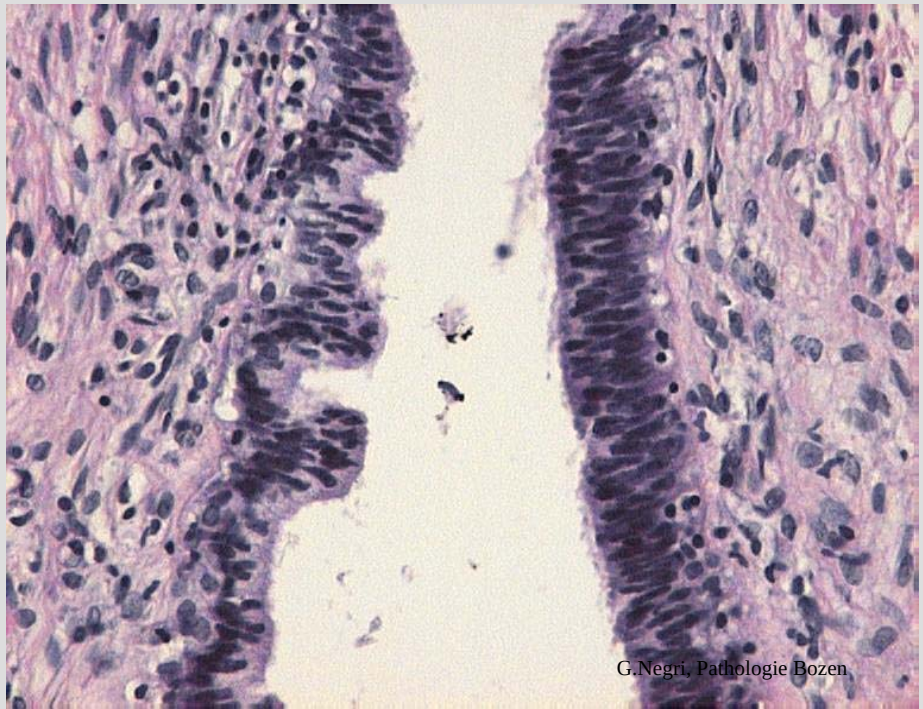

Ioffe et al, 2003: Proposal of a new scoring scheme for the diagnosis of noninvasive endocervical glandular lesions

- Stratificazione 0-3
- Atipia nucleare 0-3
- Mitosi e apoptosi 0-3

  – Score 0-3: benigno
  – Score 4-5: displasia (CGIN)
  – Score 6-9: AIS

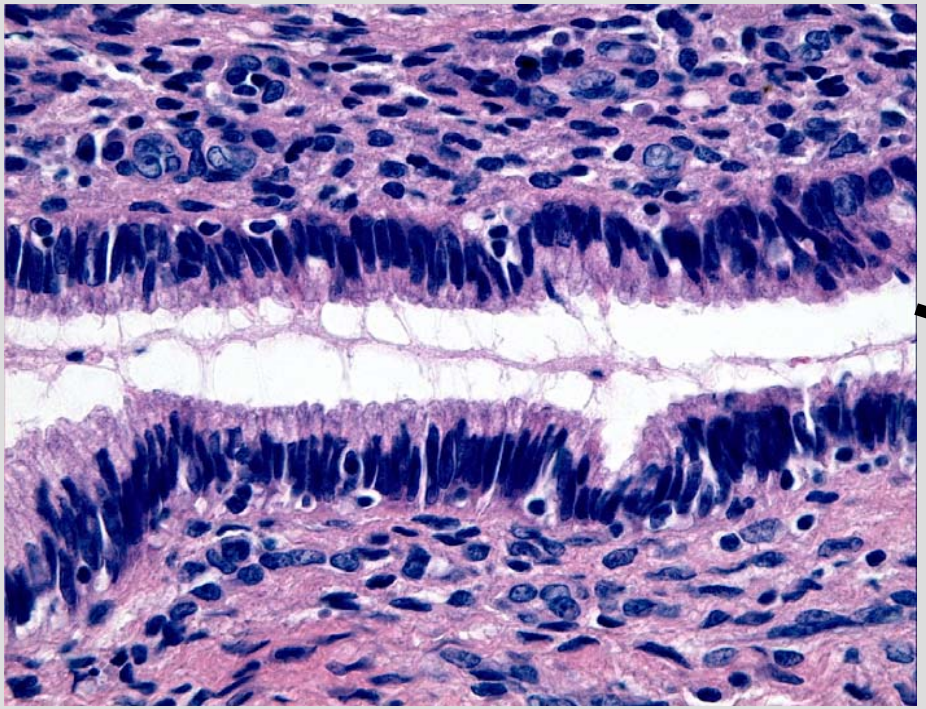

Score: 5
(CGIN)

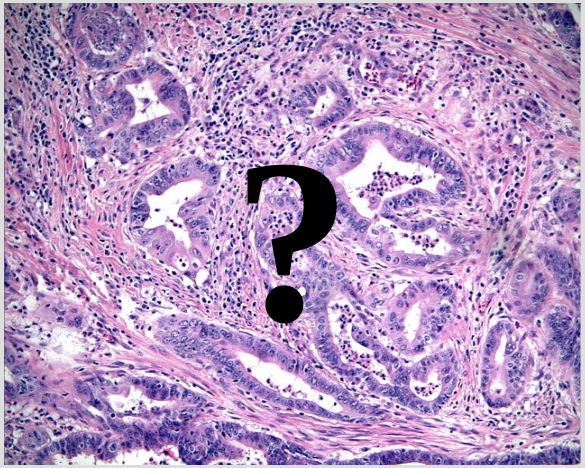

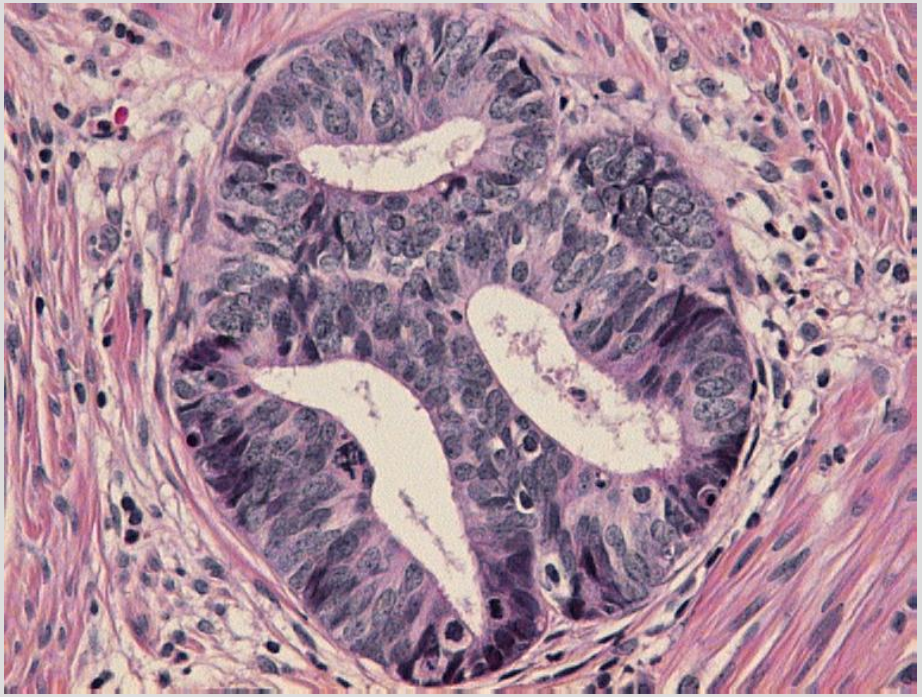

Score: 7
(AIS)

G.Negri, Pathologie Bozen

Kurian et al, JCP 1999

- “there is a progressive increase in age af patients from LGCGIN to invasive disease, a span of app. 10 years”
  - LGCGIN 39 y.
  - HGCGIN (AIS) 43 y.
  - Adenocarcinoma 48 y.
- “…it is not clear whether all or some LGCGIN would eventually progress to HG or invasive adenocarcinoma”

Lee KR (2002): “Should Pathologists Diagnose Endocervical Preneoplastic Lesions less thanAdenocarcinoma In Situ?”

- HGCGIN é frequentemente associata a casi di AIS?
  - No, in 8/117 casi
- Esistono piccoli AIS senza HGCGIN associata?
  - Sí. Possibile insorgenza di AIS de novo?
- HGCGIN é associata ad HPV?
  - Non esistono studi su HG- CGIN“pure”
- L’indice proliferativo (ki-67) di AIS e HGCGIN é simile?
  - Sí, solitamente.

Lee et al, 2000

- 6,8% CGIN associato ad AIS+
- HGCGIN associati ad AIS+:
  - 9 HPV+, 6 Ki67>25%
  - 3 HPV-, 2 Ki67<25%
- 3 HGCGIN non associati ad AIS+:
  - 3 HPV-, Ki67<25%
- 10 LGCGIN non associati ad AIS+:
  - 9 HPV-, 2 (1HPV+) Ki67>25%

Lee KR: High-grade CGIN

- “High-grade dysplasia (HGCGIN) is similar to AIS”
- “The clinical reaction to a diagnosis of endocervical dysplasia or LGCGIN is unpredictable”
  - Inclusione di HGCGIN in AIS
  - Escludere le LGCGIN e parlare di “atipia” generica nei pochi casi restanti una volta escluse le alterazioni reattive.

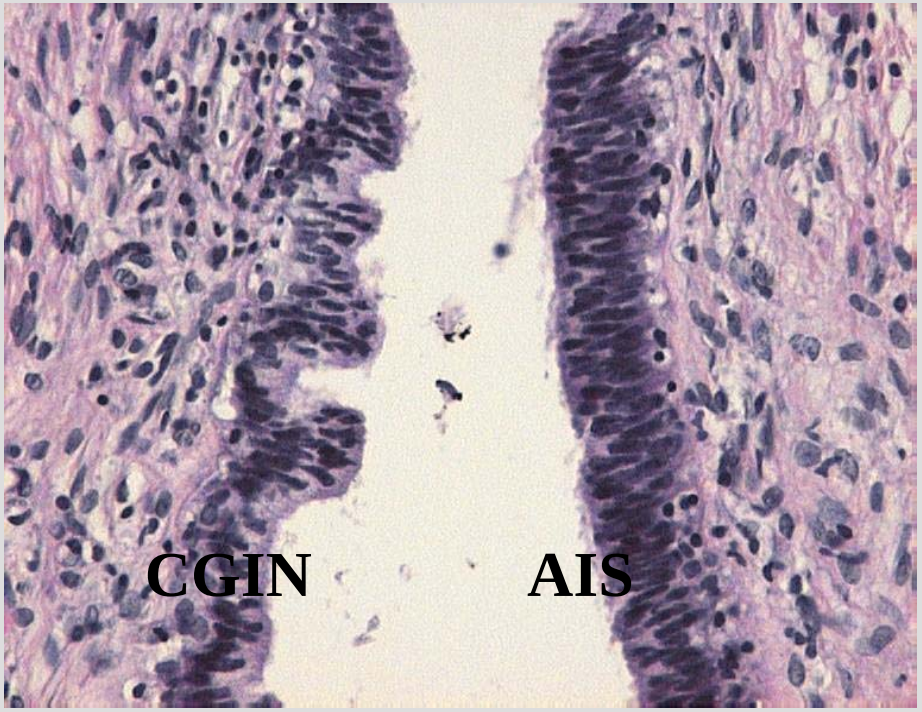

IAC compendium 1997

A van Aspert:

- ECCIN1 mild atypia
- ECCIN2 moderate atypia
- ECCIN3 severe atypia
- ECCIN4 AIS

DC Wilbur:

"…reproducible histologic and cytologic criteria for the diagnosis of endocervical dysplasia are not well-established"

"…such diagnoses may be highly subjective with poor reproducibility and completely unknown biologic significance"


G.Negri, Pathologie Bozen

AGC/CGIN a Bolzano

- Citologia:
  - HPV+ -> AGC
  - HPV- -> negativo/controllo su SS
- Istologia:
  - Ki67>25%, p16+++ -> HGCGIN/AIS
  - Ki67<25%, p16- -> negativo
  - Borderline -> controllo su SS